

# Ultrasound in Obstetrics and Gynecology for the Generalist

Dr S.Moola

Ob/gyn - Nelson BC

# US for the Generalist

- Ultrasound should be viewed as an adjunct tool to clinical exam and history (ie: like using performing an ECG for chest pain or using slit lamp)
- It should not be used as a diagnostic test (realm of radiology/perinatology)

# Impact of the availability of sonography in the acute gynecology unit

Z. HAIDER\*, G. CONDOUS\*, A. KHALID\*, E. KIRK\*, F. MUKRI\*, B. VAN CALSTER†, D. TIMMERMAN‡ and T. BOURNE\*

- 1000 consecutive women
- Of the 521 women with a positive pregnancy test, 75.6% were reassured immediately that their pregnancy was intrauterine.
- 143 women (27.4%) were given the diagnosis of a suspected ectopic pregnancy before sonography, compared with 29 (5.6%) after.

- Following the ultrasound examination there was a change in clinical management in 54.1% of the women with a positive pregnancy test and a reduction in admissions (including inpatient theater admissions) (from 40.3% to 17.1%) and outpatient follow-up examinations (from 41.1% to 35.5%).
- In 90 (23.8%) non-pregnant women a significant ovarian cyst ( $> 5$  cm) was suspected clinically; 28/90 (31.1%) were confirmed on sonography.

- Following the ultrasound examination there was a change in clinical management for 38.1% of non-pregnant women and a reduction in admissions (from 37.1% to 19.4%) and outpatient follow-up examinations (from 25.7% to 18.1%).

# Ob/Gyn US

- Know how to turn machine on
- Know how to turn machine off
- Know how to clean probes
- Know how to document observations

# Indications for pelvic ultrasound

- PV bleeding in ? pregnancy
  - Confirm IU pregnancy
  - ? Ectopic pregnancy
- Pelvic pain
  - ? Ectopic pregnancy
  - Tubo-ovarian abscess
  - Torsion of ovarian cyst...

# Scan Protocol



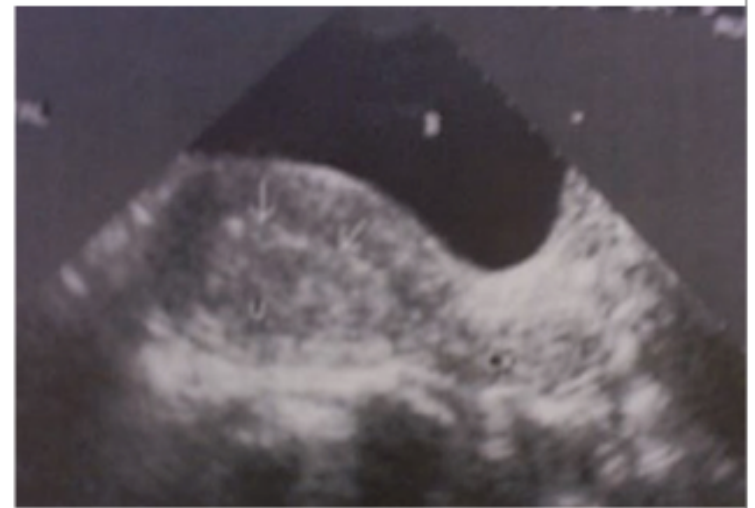
- Scan the uterus in 2 planes
- Document gestational sac or empty uterus
- Measure Sac Diameter/ Crown Rump Length
- Document foetal cardiac activity by M-B mode if possible
- Scan the adnexals & POD
- Scan Morison pouch, kidney PRN



# Transabdominal Sonography (TAS)



- Full bladder as sonic windows
- Don't over-distend bladder
  - compressing uterus and ovaries
  - uterus too far into far field
- Patient in supine position
- Two basic imaging planes:
  - sagittal
  - transverse

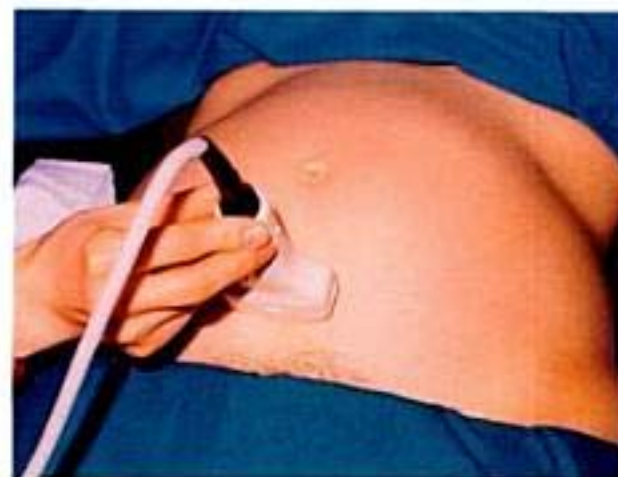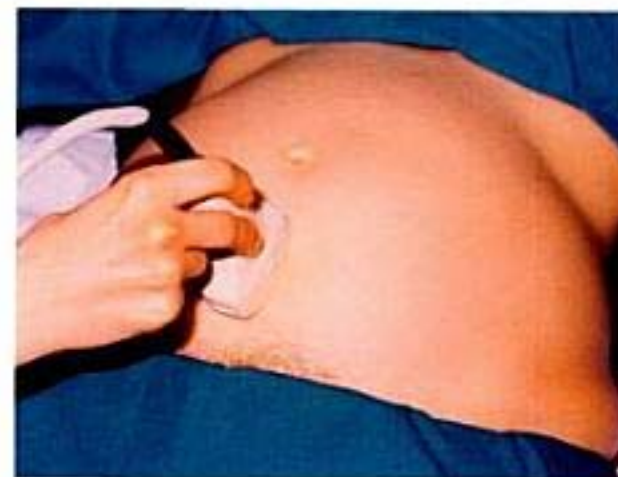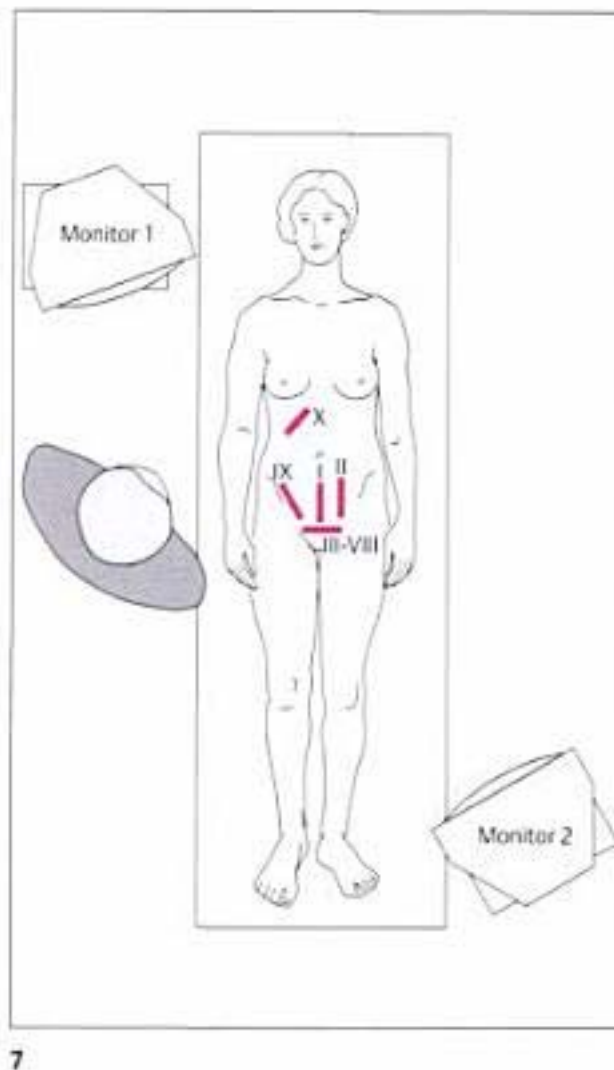


### Abdominal ultrasound

Fig. 1.7 Setup for abdominal ultrasound. The examiner sits to the left of the patient. Separate monitors are provided for the examiner and patient. I = Midsagittal scan, II = lateral sagittal scan, III-VIII = suprasymphyseal transverse scans, IX and X = oblique scans.

Fig. 1.8 Transducer placement for a midsagittal scan.

Fig. 1.9 Transducer placement for a suprasymphyseal transverse scan.



# Transvaginal Sonography (TVS)



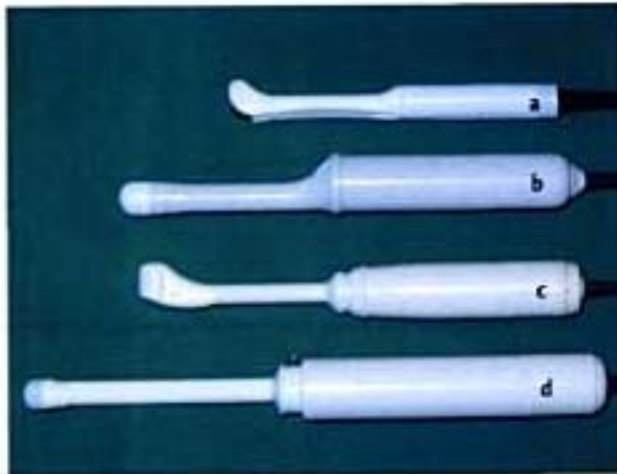- Consent & chaperon
- Empty the bladder
- Pelvic table + lithotomy position
- Alternate: pillow under the buttocks and legs in frog position
- Small amount of sonic gel between condom and probe
- Air bubbles removed by finger swipe
- Adequate gel for lubrication and imaging



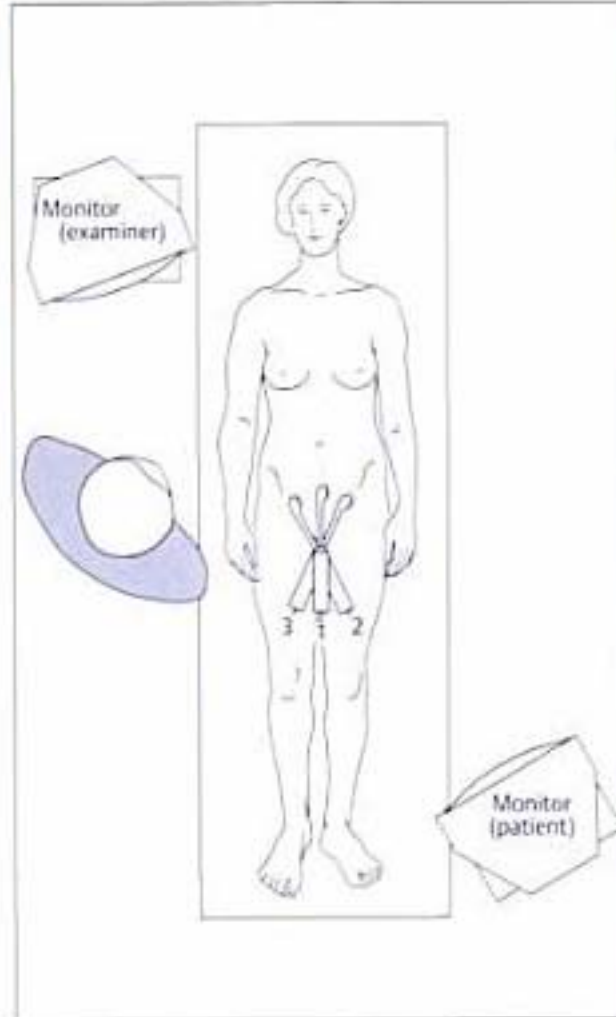
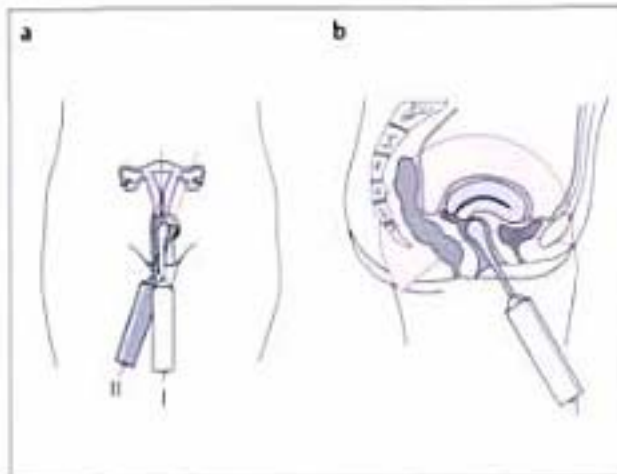
# Transvaginal Sonography (TVS)

- Watch the screen during insertion
- Compress the anterior & posterior wall of the bladder to scan the uterus
- Avoid excessive insertion which will scan the cervix and miss the uterus
- Basic planes: sagittal; coronal
- Remove condom, clean & disinfect probe after use





1



## Transvaginal ultrasound

Fig. 1.1 **Ultrasound** probes for transvaginal use.

**a, b** Electronic end-fire probes.

**c** Mechanical panoramic end-fire probe.

**d** Mechanical side-fire probe (chiefly for endorectal use).

Fig. 1.2 Setup for transvaginal **ultrasound** on an examination table. The examiner sits to the left of the patient. Separate monitors are provided for the examiner and patient.

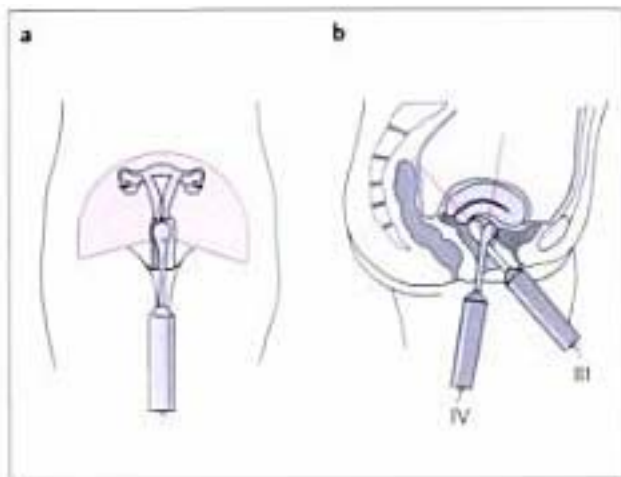
1 = Midsagittal scan,

2, 3 = Oblique scans through the lower pelvis.

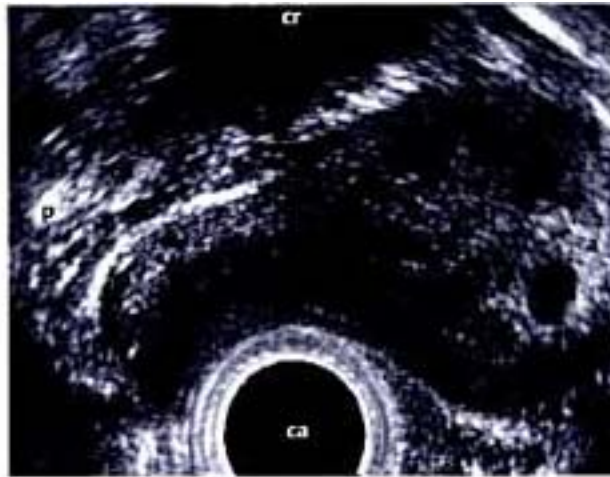
Fig. 1.3 Schematic representation of longitudinal scan planes in transvaginal **ultrasound** with a 240° end-fire probe.

**a** AP view (I = longitudinal midline scan, II = oblique longitudinal scan).

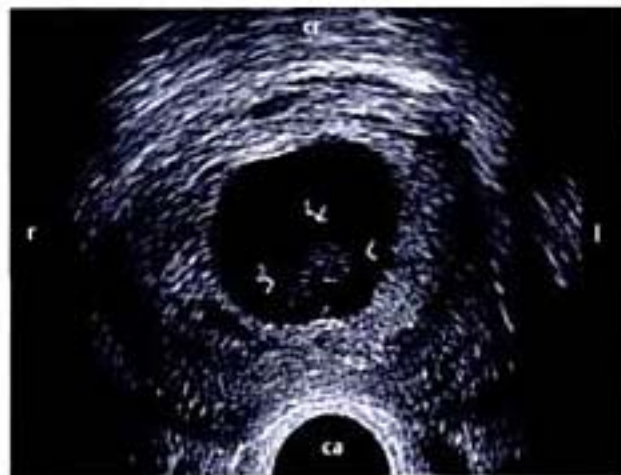**b** Lateral view of a longitudinal midline scan.



4



5



6

**Fig. 1.4** Schematic representation of coronal scan planes in transvaginal ultrasound with a 240° end-fire probe.  
**a** AP view. For clarity, the uterus is shown in a straightened position.  
**b** Lateral view (III = transverse scan through the cervix, IV = transverse scan through the uterine corpus).

**Fig. 1.5** Longitudinal scan through a gravid anteverted uterus at 5 weeks, 5 days. The probe is in the anterior fornix.  
cr = superior, ca = inferior, p = posterior, a = anterior

**Fig. 1.6** Transvaginal coronal scan shows a cross-sectional view of the uterine cavity at 8 weeks, 1 day. The markers indicate the size of the amniotic cavity. A section of the corpus luteum appears on the patient's left side.  
cr = superior, ca = inferior, r = right, l = left



# TVS VS. TAS

## ■ Advantages of TVS:

- higher frequency means better axial resolution
- bladder can be empty
- no bowel gas to interfere with image
- no subcutaneous fat to penetrate
- earlier detection of gestational sac

## ■ Disadvantages of TVS:

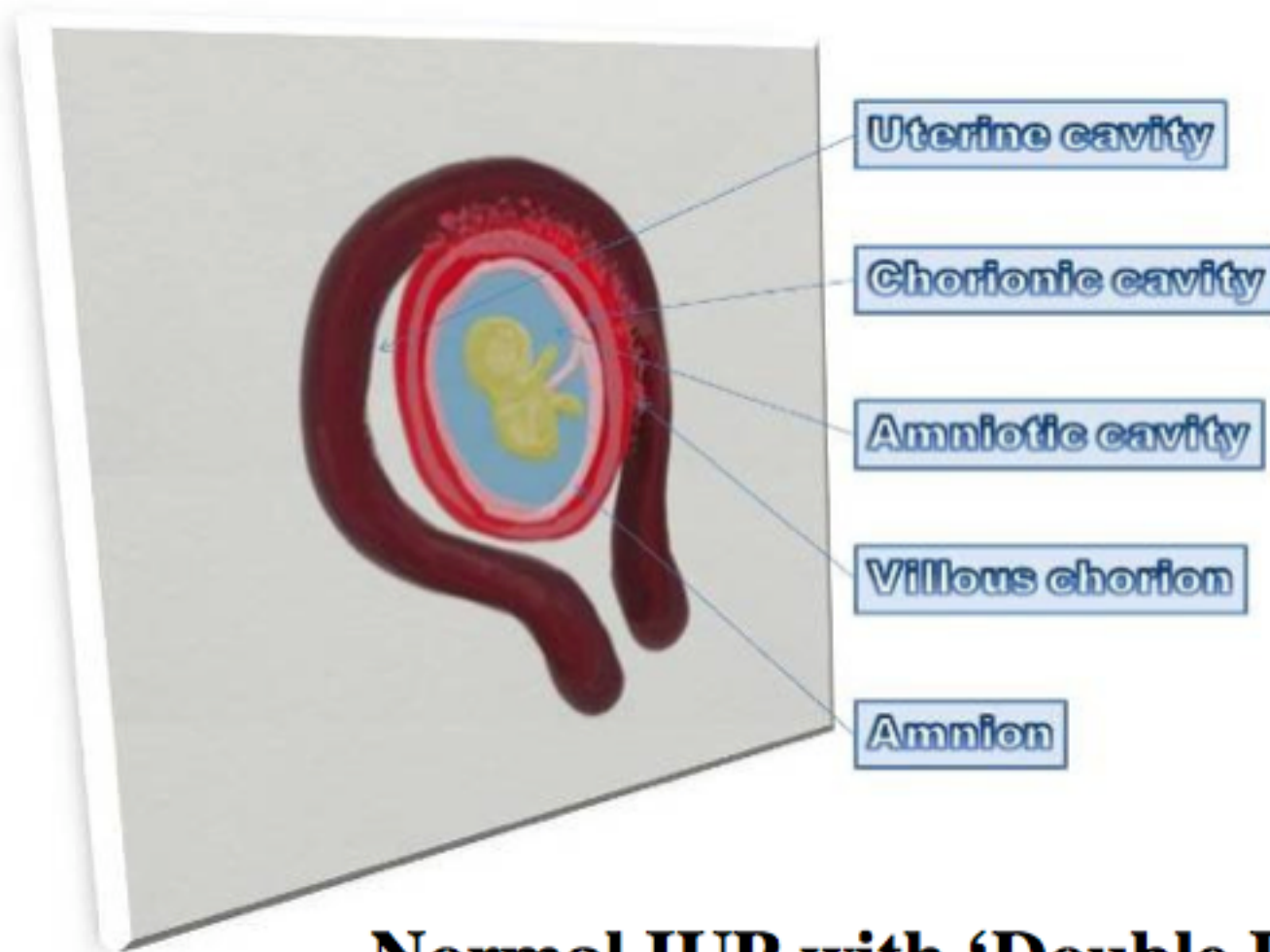
- limited field of view
- limited maneuverability of the transducer
- wall of bladder can create an artifact over the cervix, if bladder is not empty

First look for an IU pregnancy...

Then, see if IUP is viable and corresponds to date

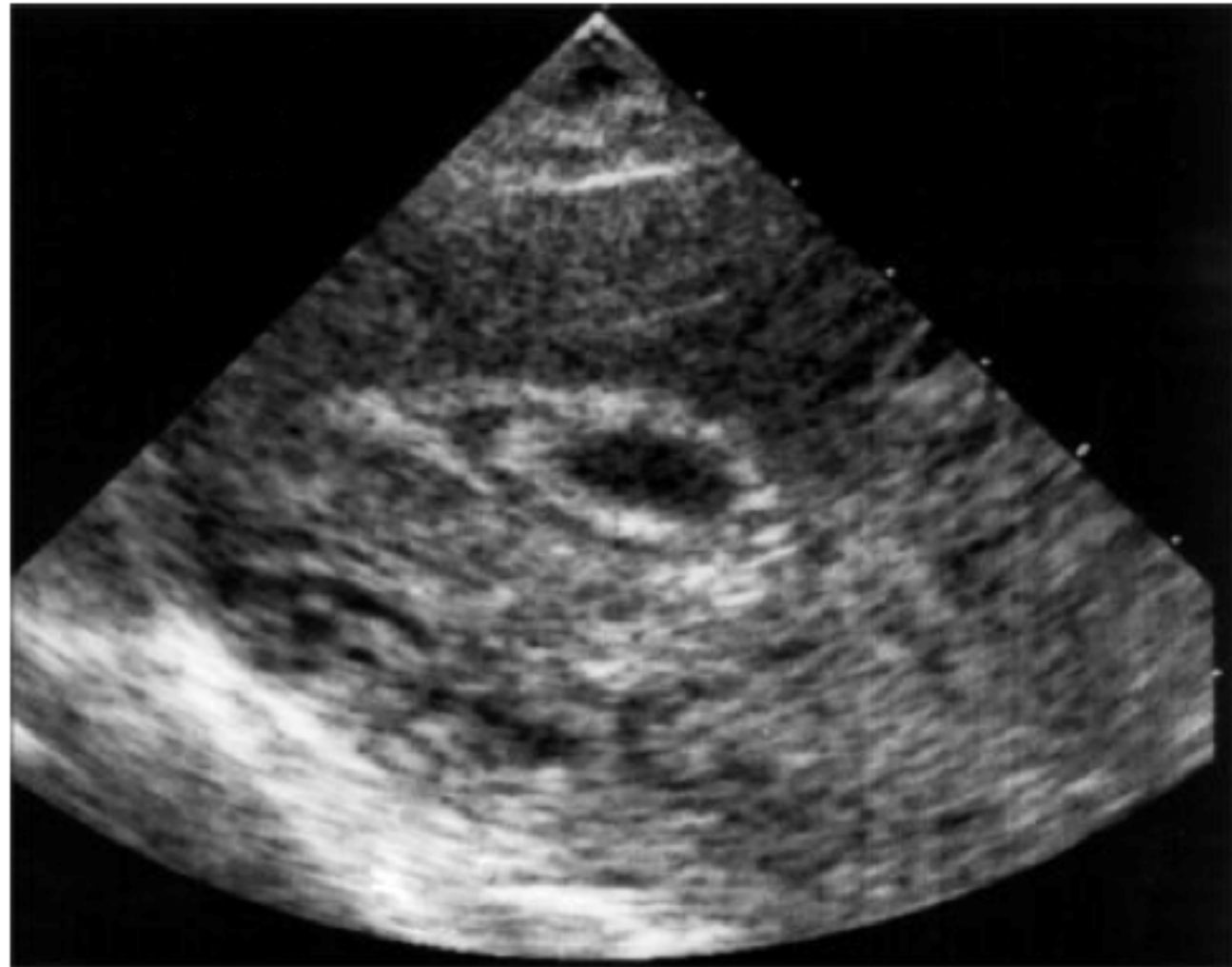


# Normal IUP



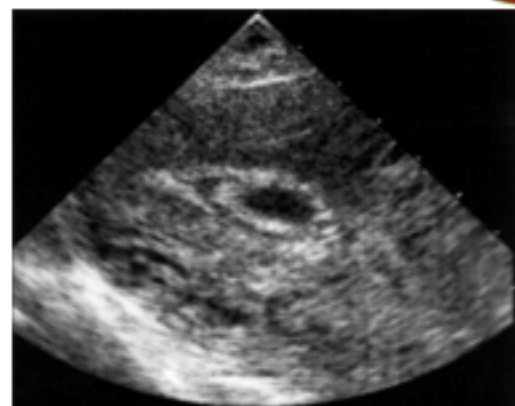
**Normal IUP with 'Double Decidual'**

# Normal IUP



**Normal IUP with 'Double Decidual Sac'**

# Sonographic Evidence of a Normal Gestational Sac



<u>Feature</u>	<u>Description</u>
----------------	--------------------

Shape	Round or oval
-------	---------------

Position	Fundal or middle portion of uterus; a centre position (but eccentric to endometrium)
----------	--

Contour	Smooth
---------	--------

Wall	Yolk sac present when MSD > 8mm; embryo present when MSD > 16mm
------	---

Growth	1mm/day (range: 0.7 to 1.5 mm/day)
--------	------------------------------------

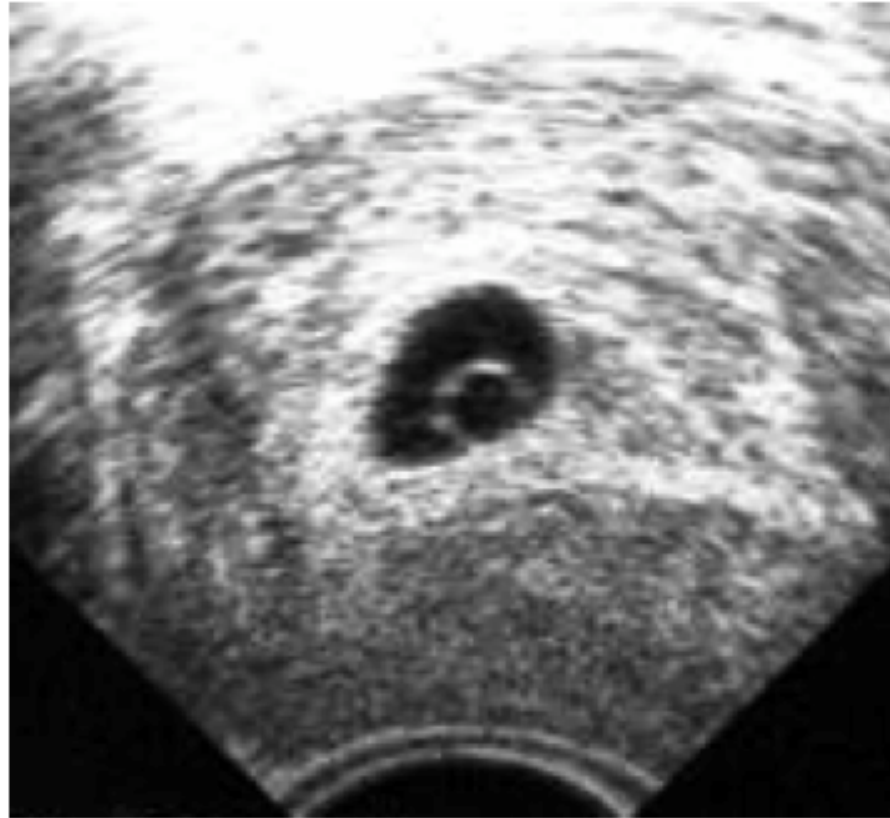
# Dating the IUP



## Earliest visualization of embryonic structures (TAS VS. TVS)

<i><u>Structure</u></i>	<i><u>TAS</u></i>	<i><u>TVS</u></i>
Gestational sac	5.5-6 wks	4.5-5wks
2° yolk sac	6-6.5 wks	5-5.5 wks
Foetal pole	7 wks	5.5-6 wks
Foetal parts	> 8 wks	8 wks

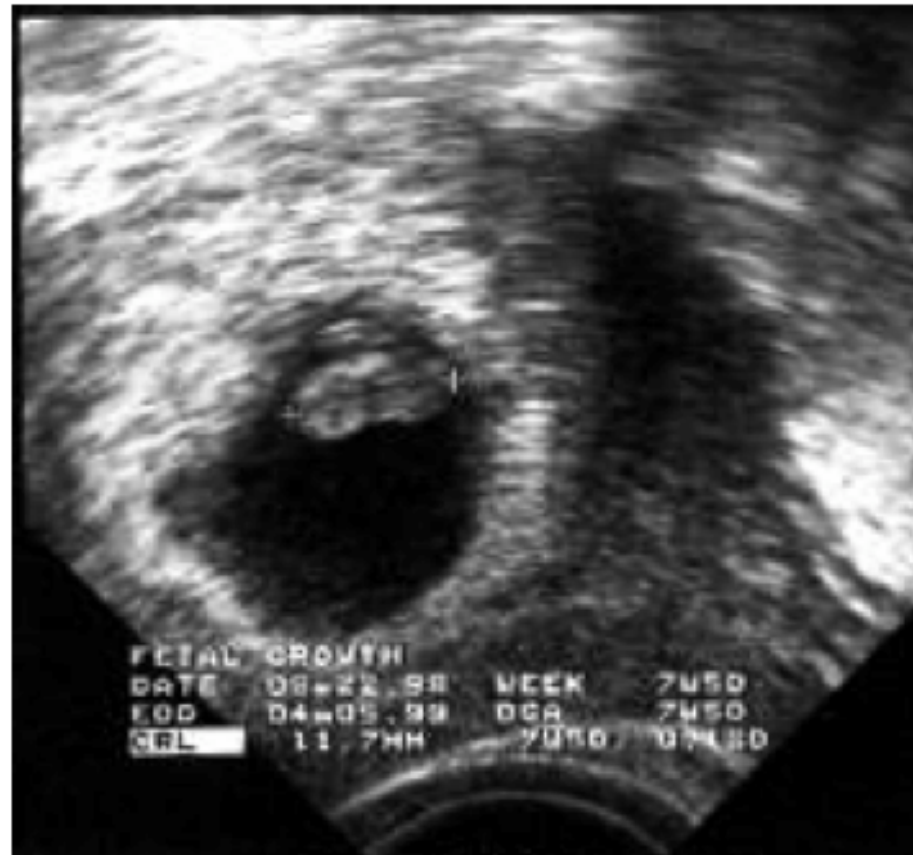# Normal IUP—yolk sac



**TVS of a 6-week IUP.**

**Yolk sac is the first sign to 'confirm' an IUP**

# Normal IUP—fetal pole



**Measurement of CRL by TVS – 7W5D**

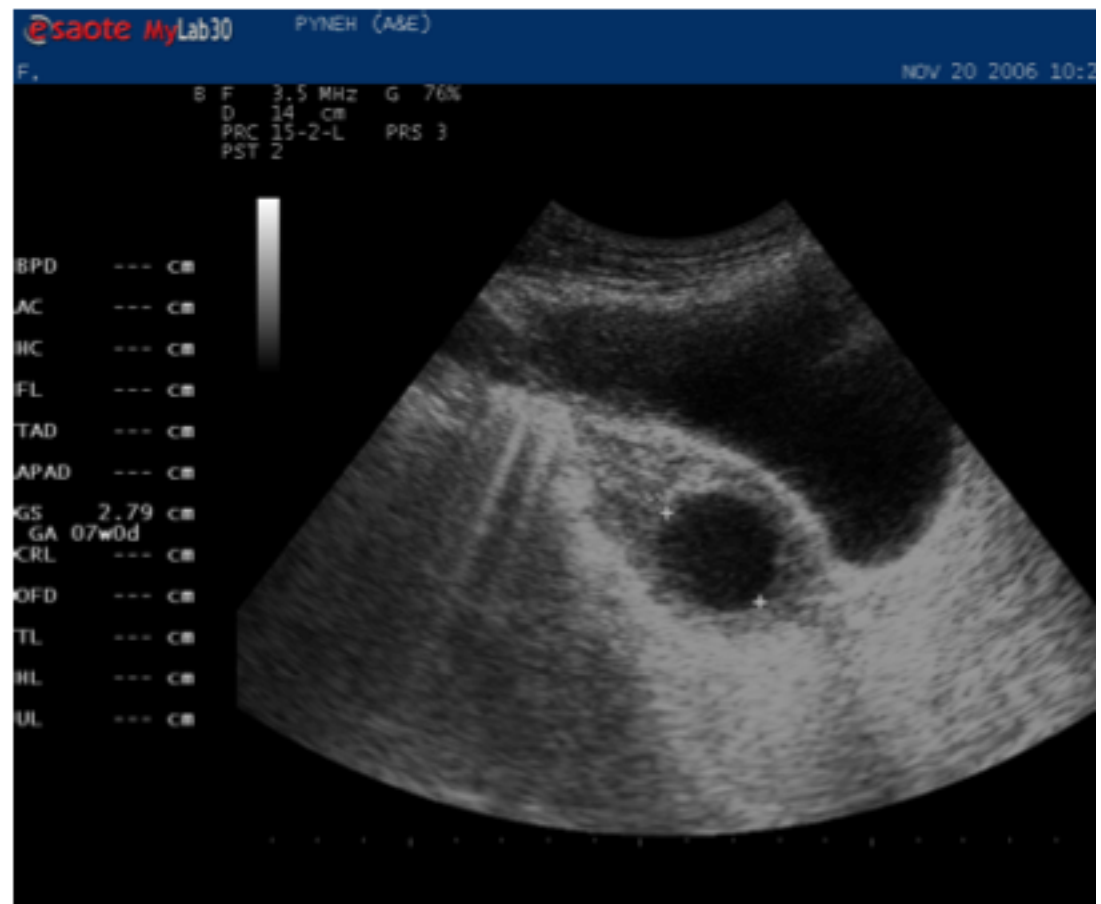
**M-B mode can be used to document cardiac activity**





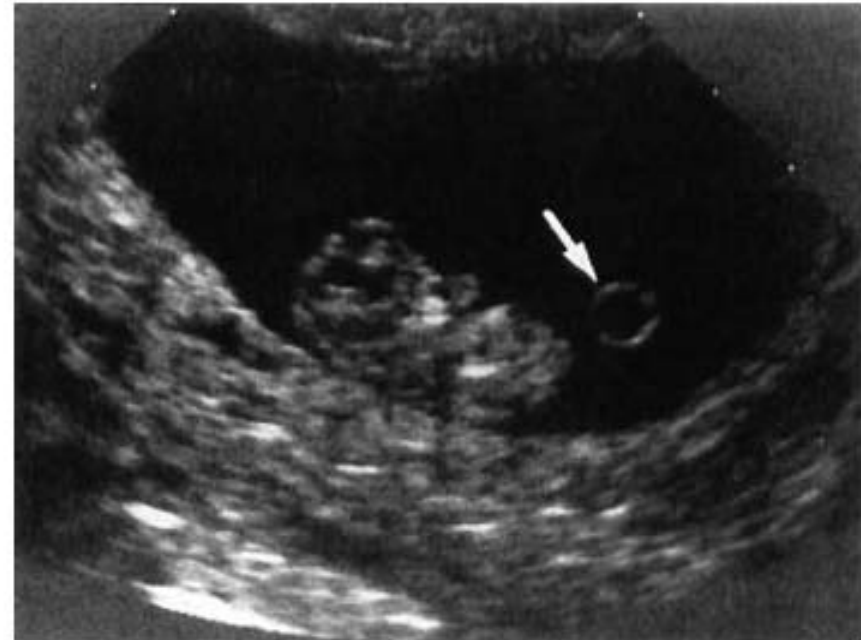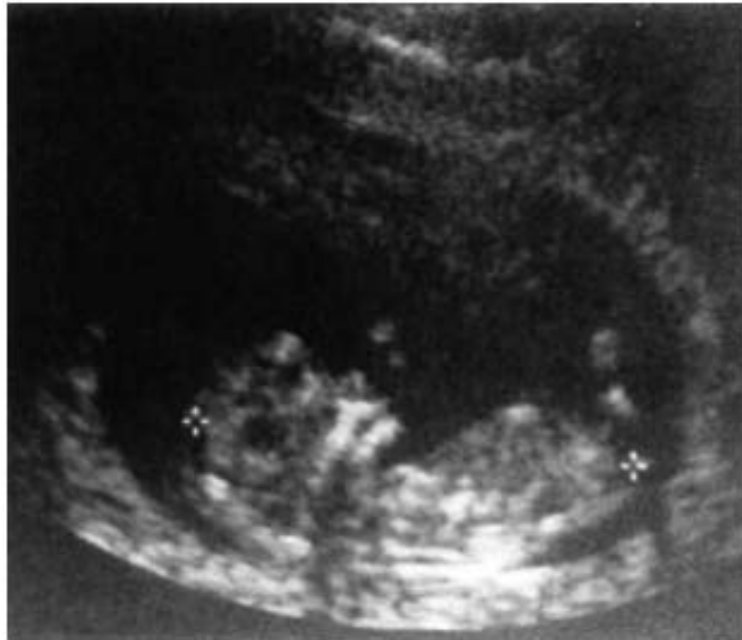
# Normal IUP—measuring MSD

- Sagittal and Coronal Scan
- Mean of three readings





# Normal IUP—measuring CRL



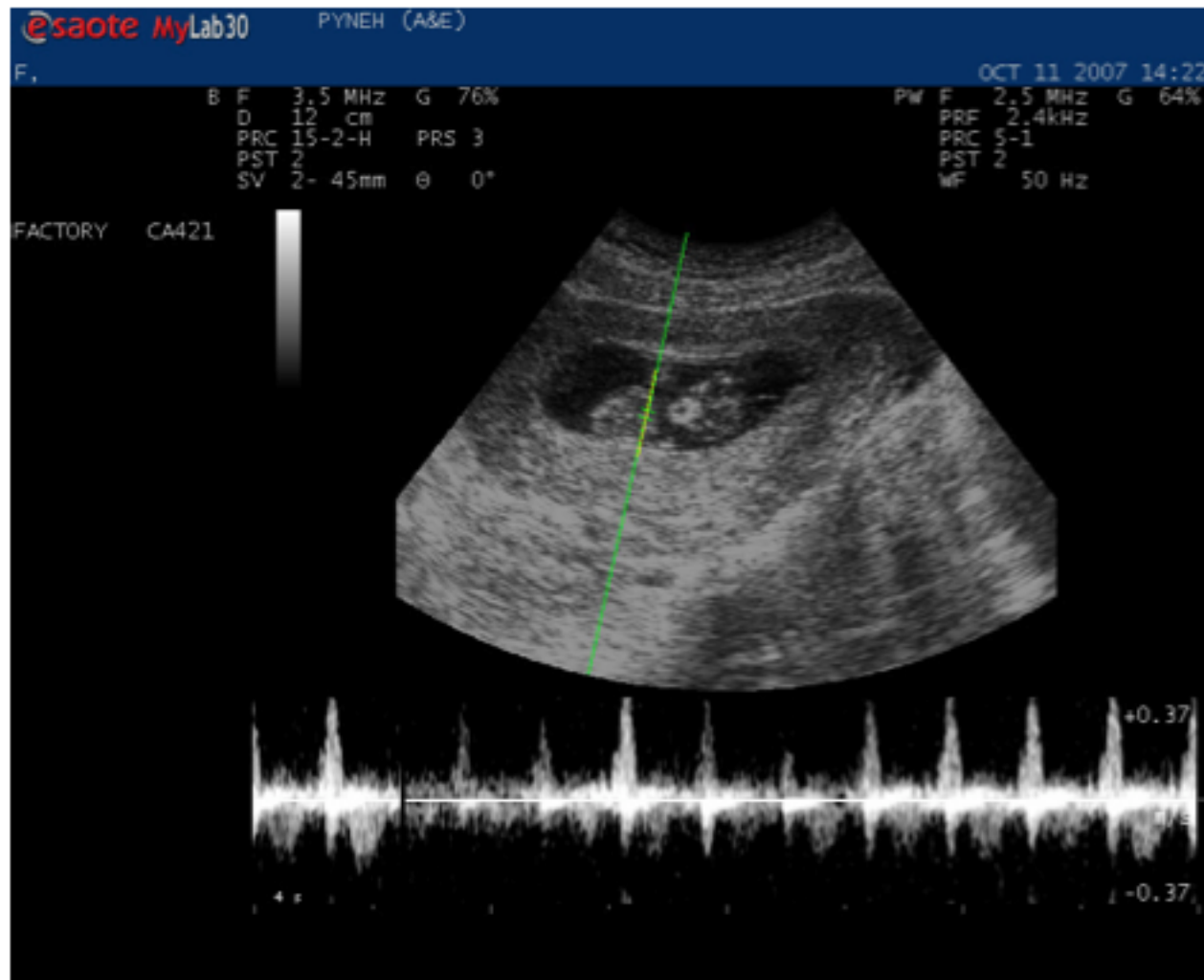
**Measurement of CRL by TVS.**

**M-B mode can be used to document cardiac activity**

$$\text{CRL (cm)} + 6.5 = \text{gestation age (wk)}$$



# Normal IUP—cardiac activity



**M-B mode can be used to document cardiac activity**

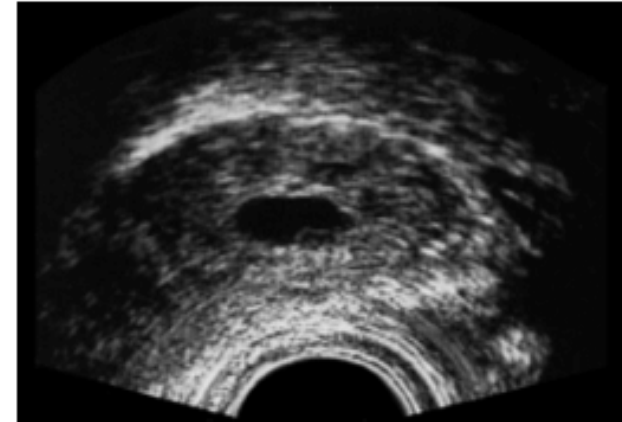
# US Diagnosis: IUP identified

- IUP identified by USG almost excludes EP
- Heterotopic pregnancy ~ 1:4000
- Criteria for IUP:
  - IU foetus with cardiac activity
  - 2<sup>o</sup> yolk sac
  - 'Double Decidual Sac' sign (3 stripes)



# US Diagnosis: IUP Pitfall

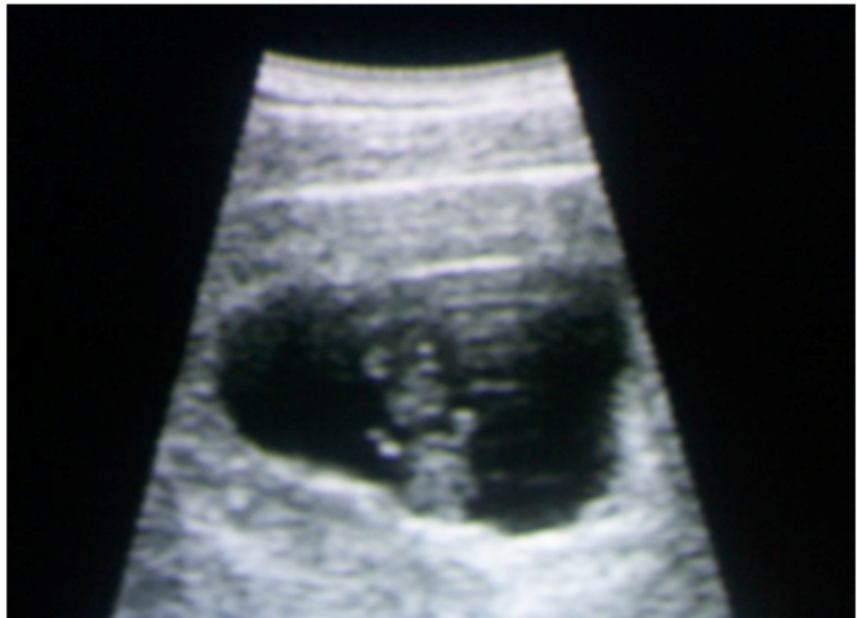- Pseudosac
  - 10-20% of EP
  - single layer
  - collection of blood cells can mimic CRL
- Women undergoing in-vitro fertilization
  - heterotopic pregnancy ~ 1/35-1/100



# US Diagnosis: Fetal Heart -ve



- Too early
  - $< 7$  wk
  - GS=date  $\Rightarrow$  TVS
- $> 7$  wk
  - GS $<7$ wk ?wrong date
  - GS= date ? Missed abortion
  - CRL  $> 10$ mm ? Missed abortion



# Incomplete / Missed Abortion



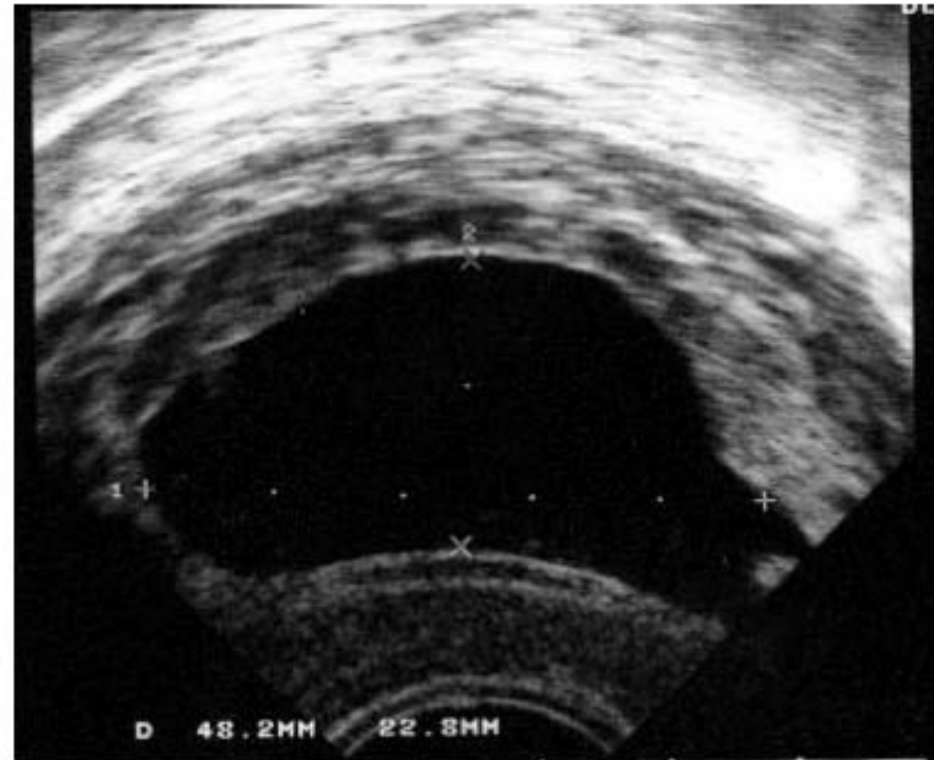- MSD > 8mm : no yolk sac
- MSD > 16mm: no foetal pole
- CRL > 10mm: no cardiac activity
- Abnormal misshapen sac
- History, LMP and date of PT +ve should be taken into account



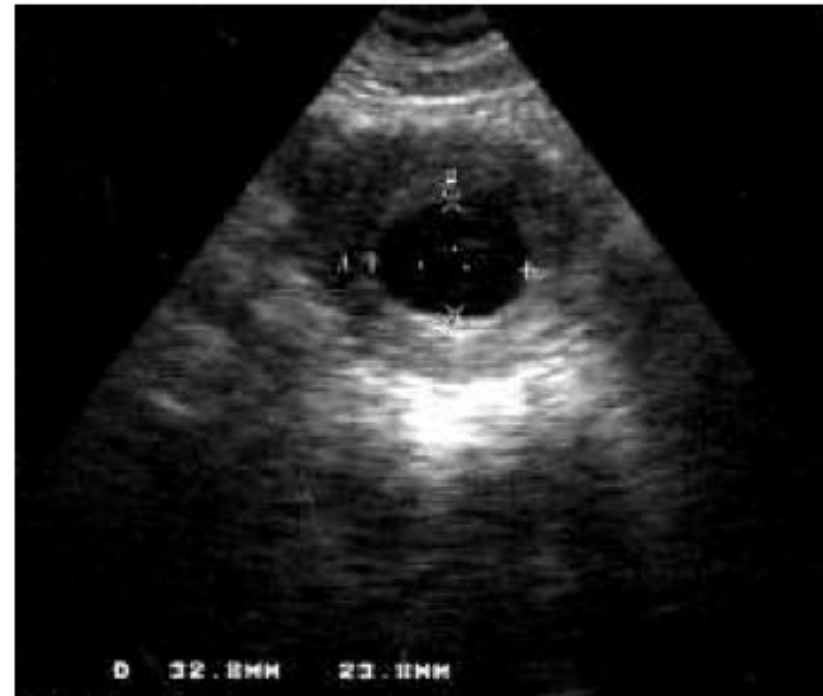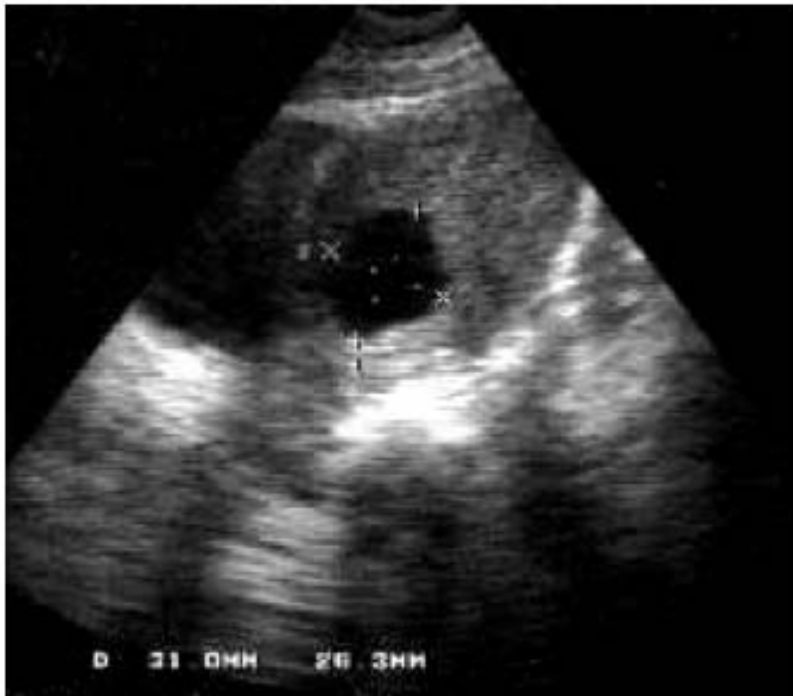# US Diagnosis: Blighted Ovum



- Empty sac
  - no yolk sac
  - no foetal pole
- MSD > 20mm



# Blighted Ovum



**Empty intrauterine sac. MSD calculated by the mean of 3 diameters in 2 views = 30mm.**

# US Diagnosis: Empty Uterus



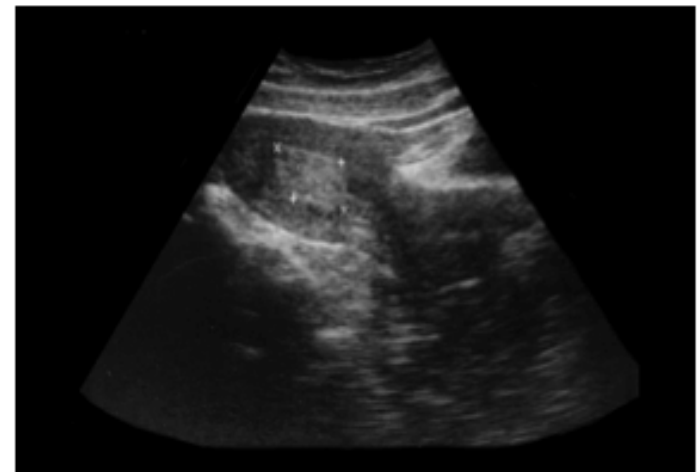
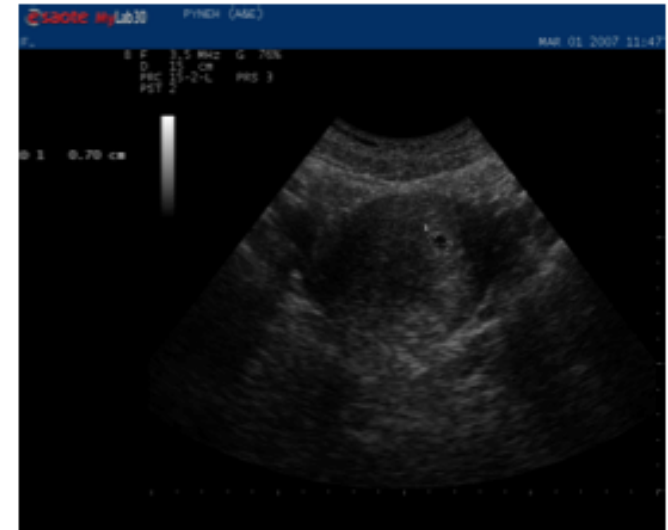
Ectopic Pregnancy Until Proven Otherwise!



# Other DDx for empty uterus



- very early pregnancy < 5 wk
- incomplete abortion
- complete abortion (definite passage of tissue mass)



# Ectopic Pregnancy

## ■ Locations

– Tubal	95%
– Abdominal	1.5%
– Ovarian	0.5%
– Cervical	0.03%

CLINICALLY STABLE FEMALES WITH LOWER ABDOMINAL /  
 PELVIC PAIN, ADNEXAL MASS/TENDERNESS, VAGINAL  
 BLEEDING, ORTHOSTASIS, OR ANY RISK FACTORS \*

↓  
**POSITIVE URINE PREGNANCY TEST**

↓  
**ENDOvaginal ULTRASOUND**

↓  
**INTRAUTERINE PREGNANCY**

Yes  
**DEFINITIVE IUP OR  
 PROBABLE ABNORMAL IUP**

↓  
**TREAT COMPLAINTS  
 FOLLOW-UP IN OB-GYN  
 CLINIC  
 CONSULT GYN FOR ANY  
 SIGNIFICANT INCIDENTAL  
 FINDINGS\*\***

No  
**DEFINITIVE ECTOPIC  
 PREGNANCY PRESENT**

Yes  
**SEND  
 PREOPERATIVE  
 LABS: CBC, SMA,  
 UA, TYPE AND  
 CROSSMATCH  
 SERUM QUANT  
 HCG  
 CONSULT GYN**

No  
**STAT QUANTITATIVE SERUM HCG  
 < 2,000 mIU (or below discriminatory  
 zone) AND NO SIGNIFICANT  
 INCIDENTAL FINDINGS \*\***

Yes  
**SEND HOME  
 GIVE ECTOPIC WARNINGS  
 ARRANGE GYN CLINIC  
 APPOINTMENT IN 48-72 HR  
 REQUEST FOR FOLLOW-UP  
 SERUM HCG AND  
 ULTRASOUND**

No  
**IF HCG > 2,000 mIU (or above  
 discriminatory zone) AND/OR  
 PATIENT BECOMES  
 CLINICALLY UNSTABLE OR  
 SIGNIFICANT INCIDENTAL  
 FINDINGS\*\*  
 CONSULT GYN**

\* **RISK FACTORS INCLUDE:**  
 | HISTORY OF PID  
 | HISTORY OF TUBAL LIGATION  
 | ABDOMINAL/PELVIC SURGERY  
 | >2 ELECTIVE ABORTIONS  
 | HISTORY OF INFERTILITY  
 | PRIOR ECTOPIC  
 | CURRENT IUD

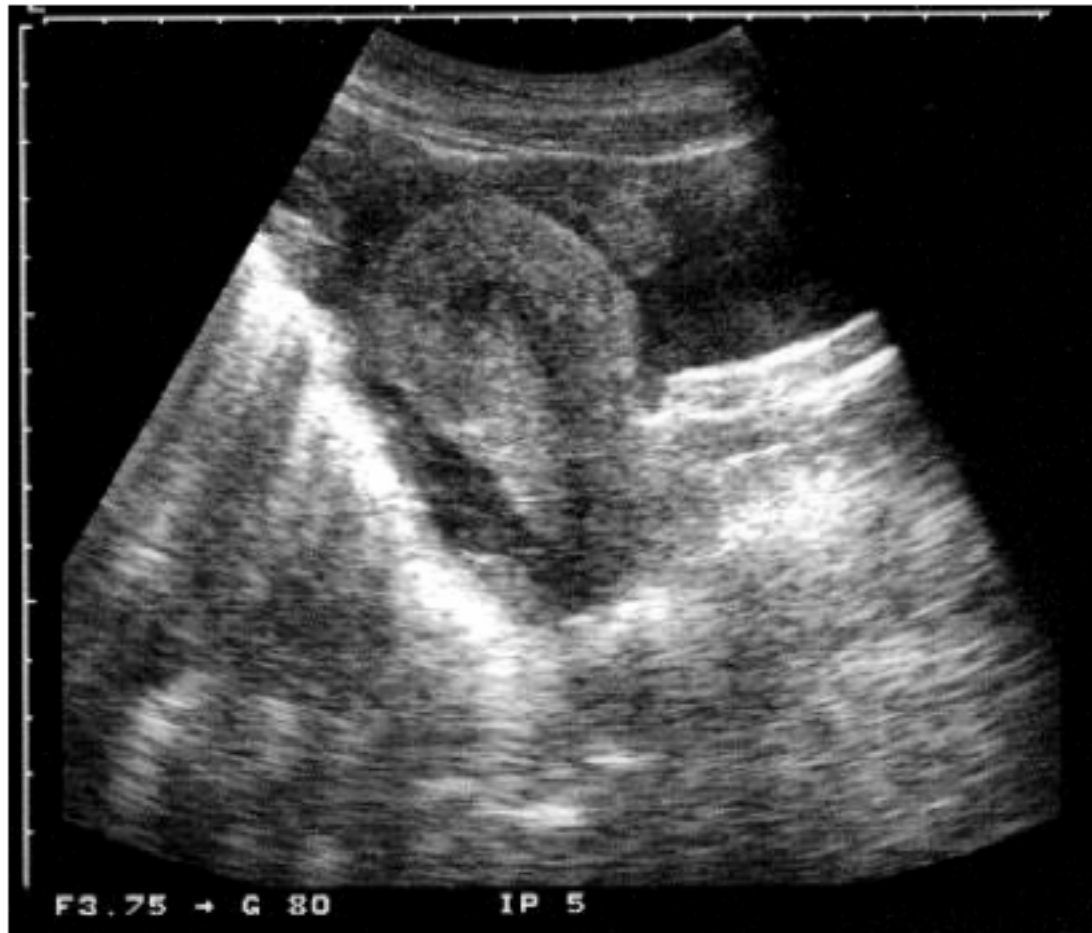\*\* **SIGNIFICANT INCIDENTAL FINDINGS:**  
 | MODERATE TO LARGE FREE FLUID  
 | ECHOGENIC MASS IN ADNEXAE  
 | TUBAL RING  
 | IUD  
 | MYOMATOUS UTERUS

# US Diagnosis: Ectopic Pregnancy



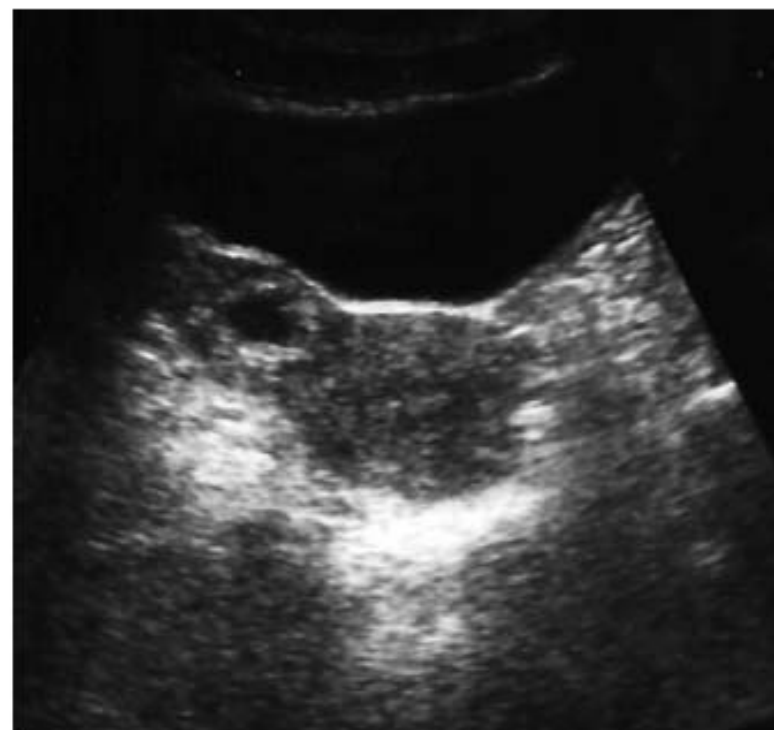
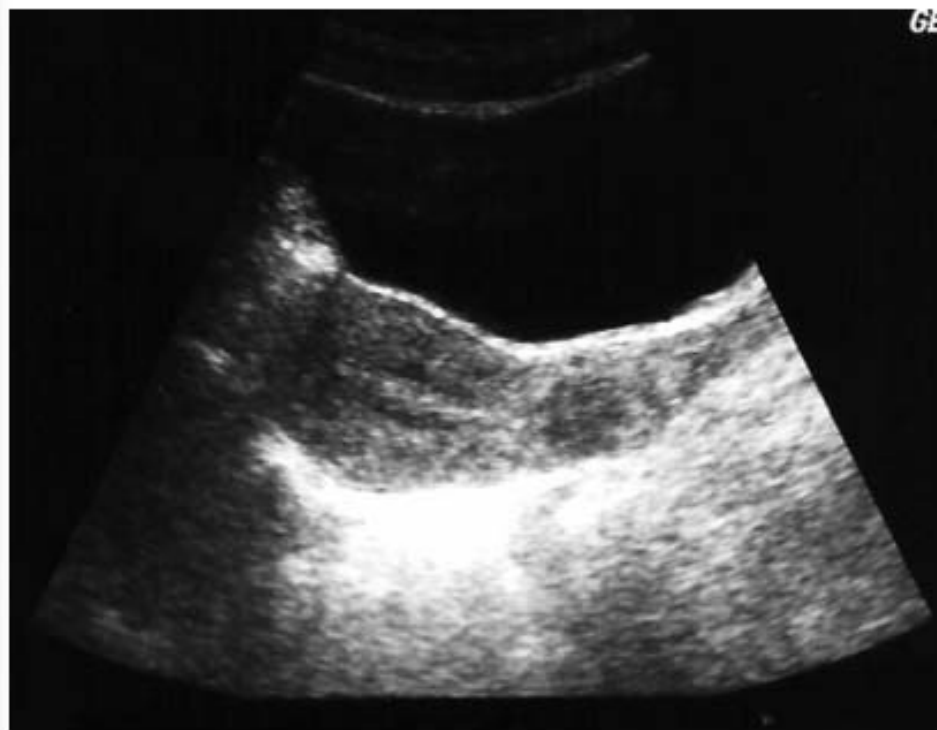- Indirect evidence suggestive of EP
  - empty uterus
  - moderate to large amount POD fluid
  - adnexal mass (adnexal ring sign)
- TIPs: scan the Morison's pouch for haemoperitoneum suggestive of rupture
- Sonographic evidence diagnostic of EP
  - extrauterine gestational sac with yolk sac
  - extrauterine gestational sac with CRL & cardiac activity (only 20% of EP with TVS)

# Ectopic Pregnancy

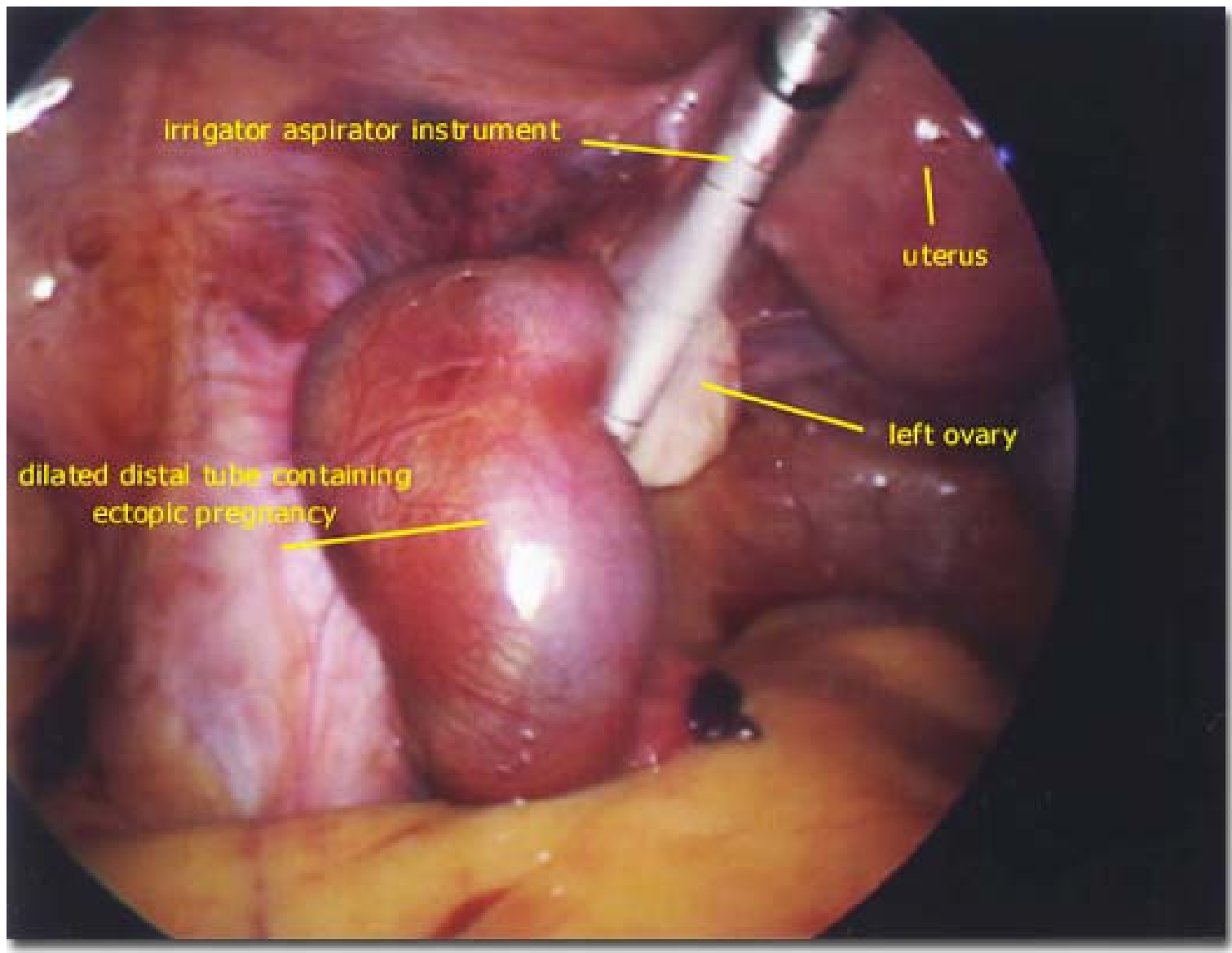


**Empty Uterus with large amount POD fluid**

# Ectopic Pregnancy



**EP in Right Adnexa, note Empty Uterus**



irrigator aspirator instrument

uterus

left ovary

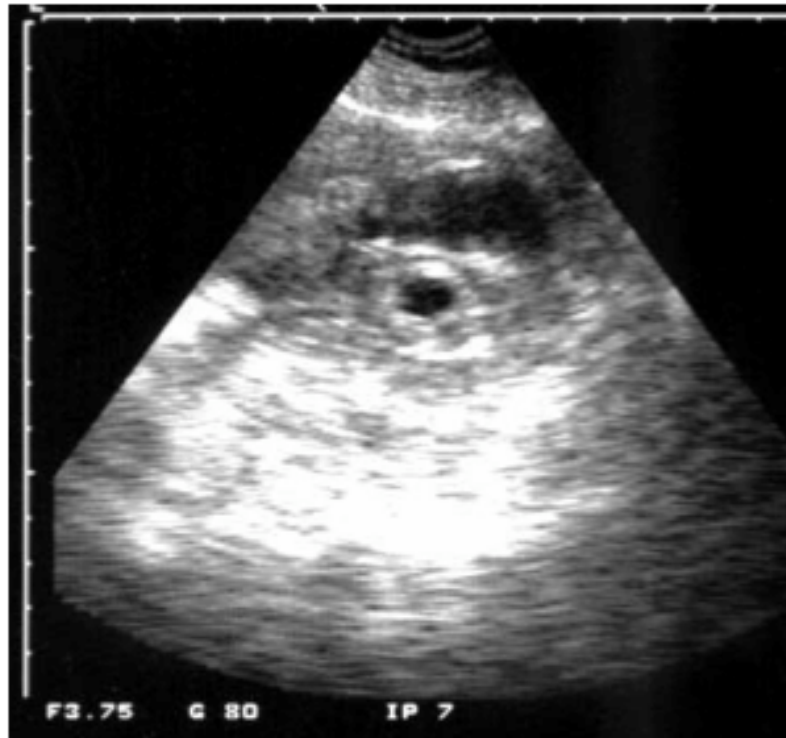dilated distal tube containing  
ectopic pregnancy



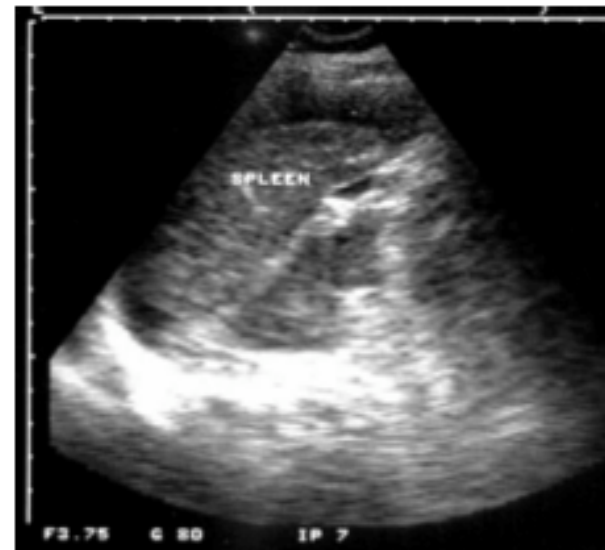# Ectopic Pregnancy (Tubal Ring)



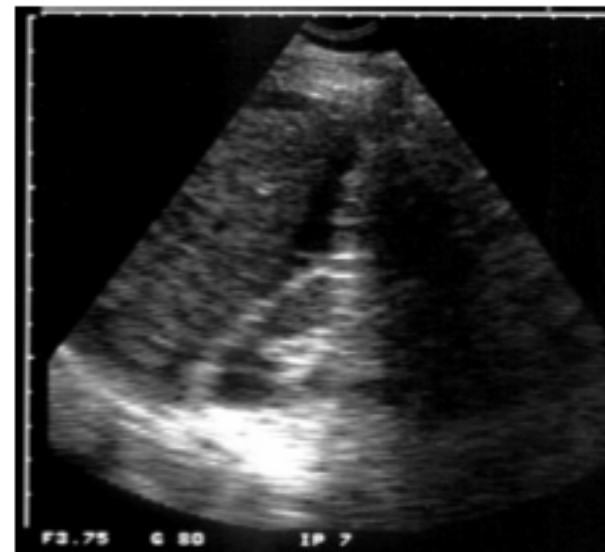*Tubal Ring*



**Ruptured EP in left adnexa  
with severe haemoperitoneum**

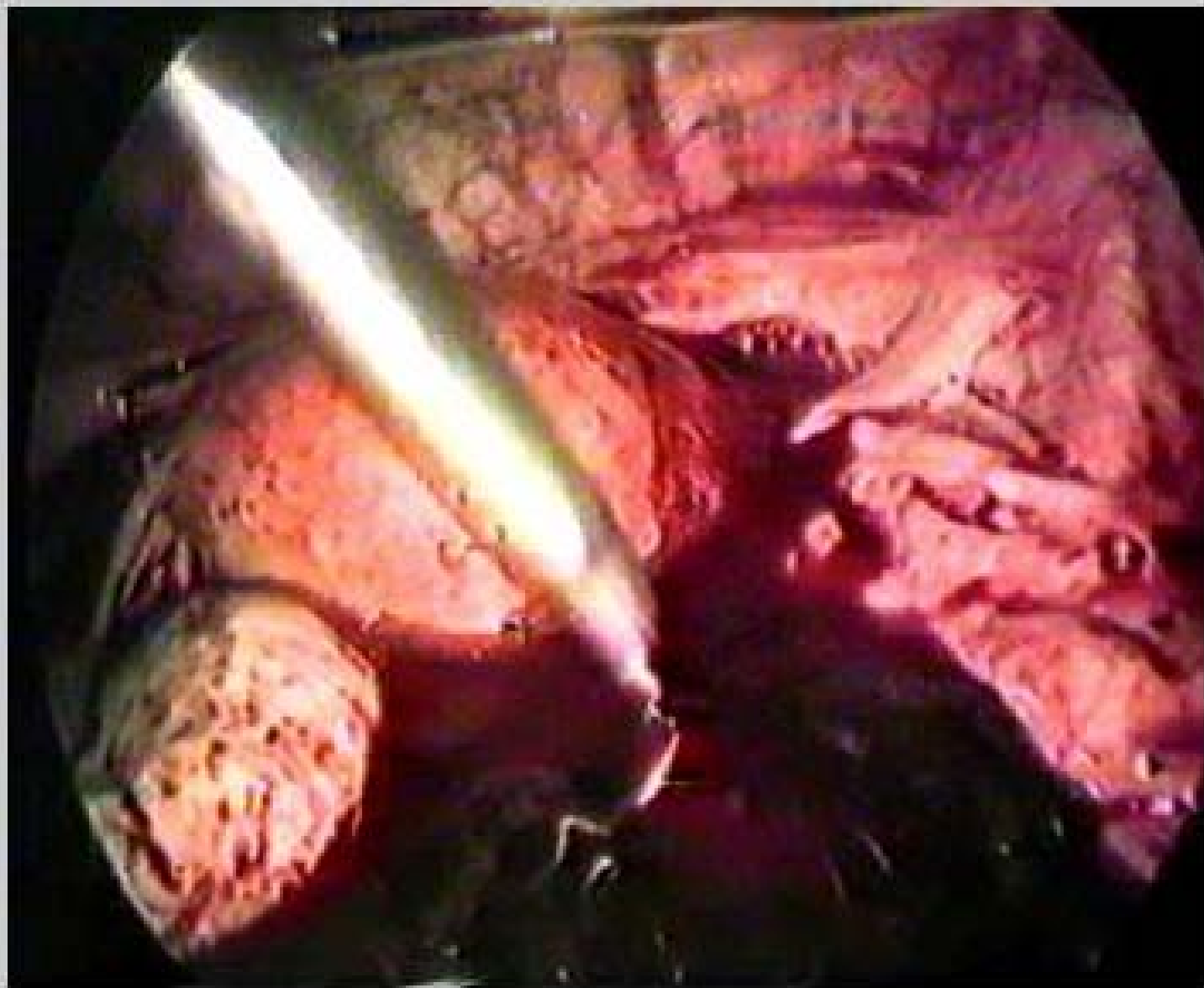


*LUQ*

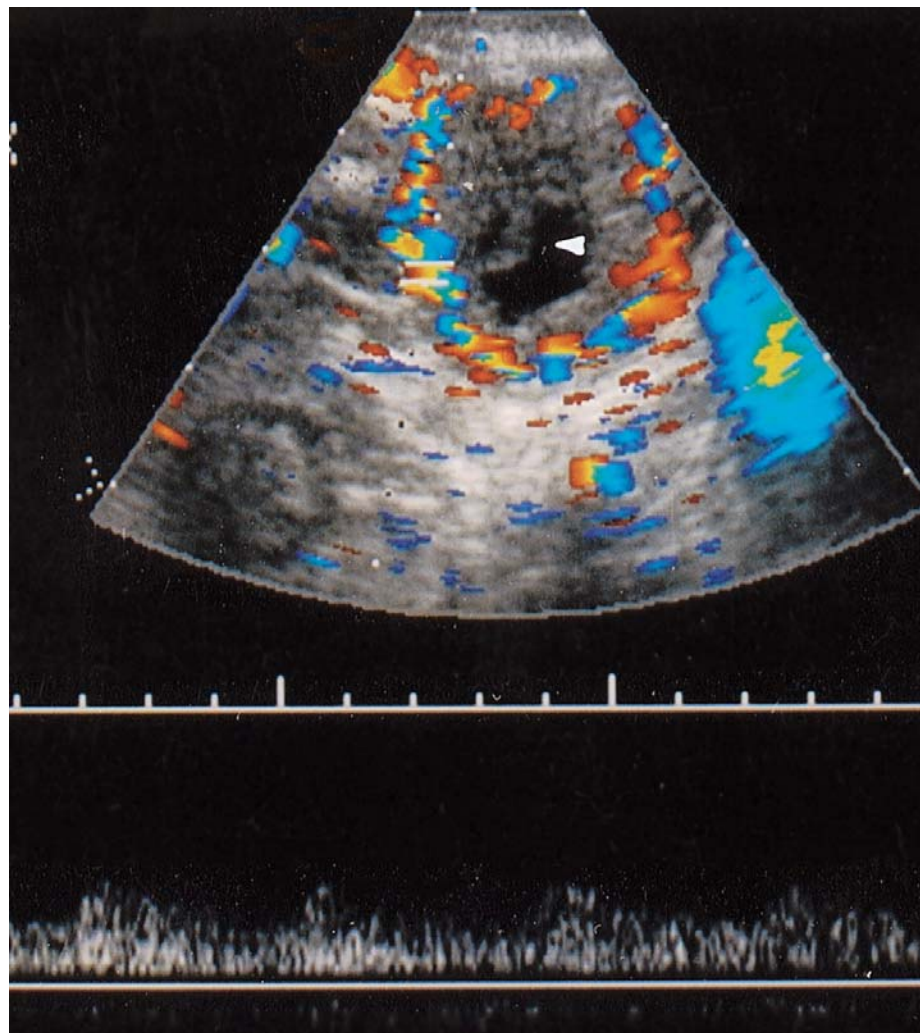


*RUQ*





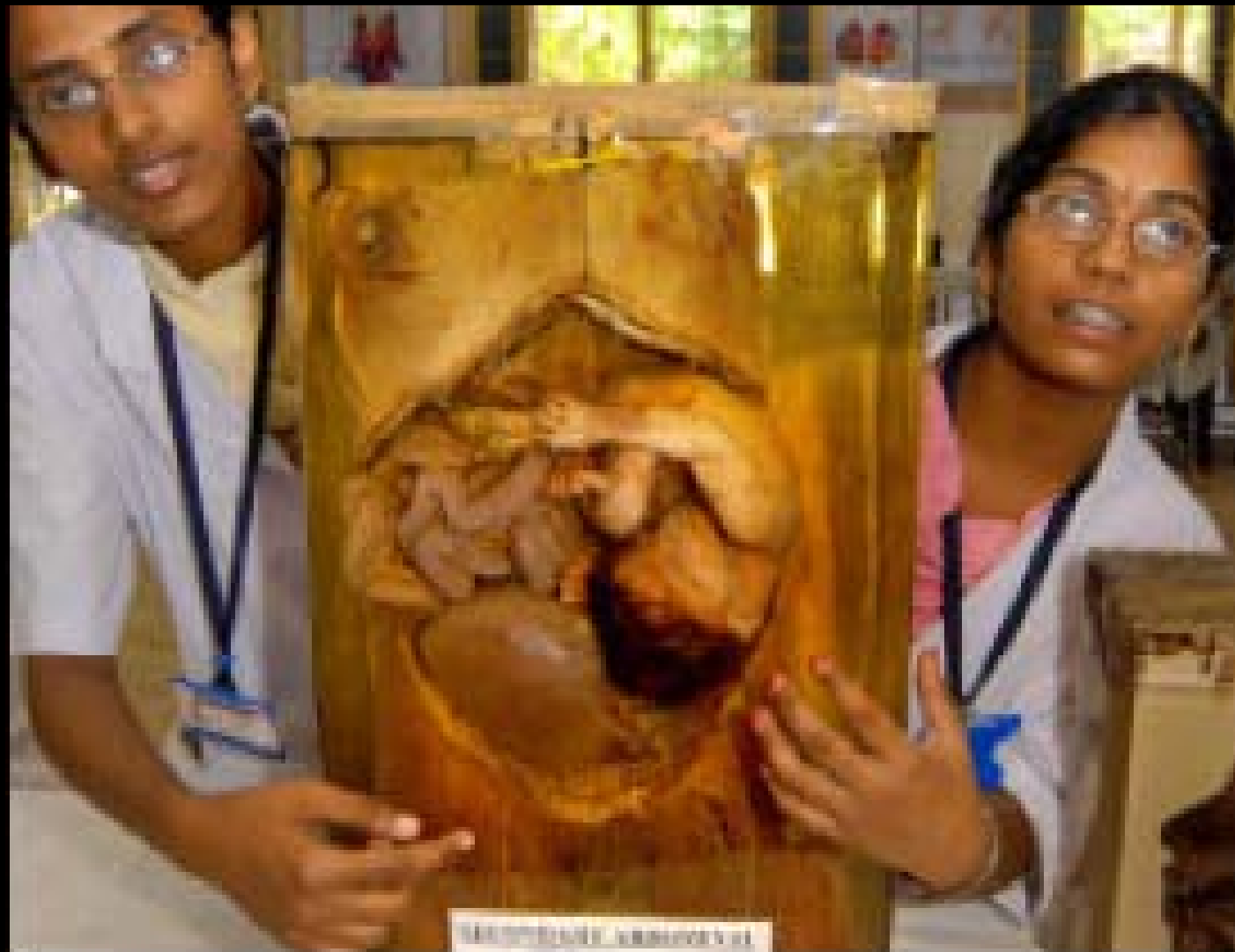--26-year-old woman with live tubal ectopic pregnancy



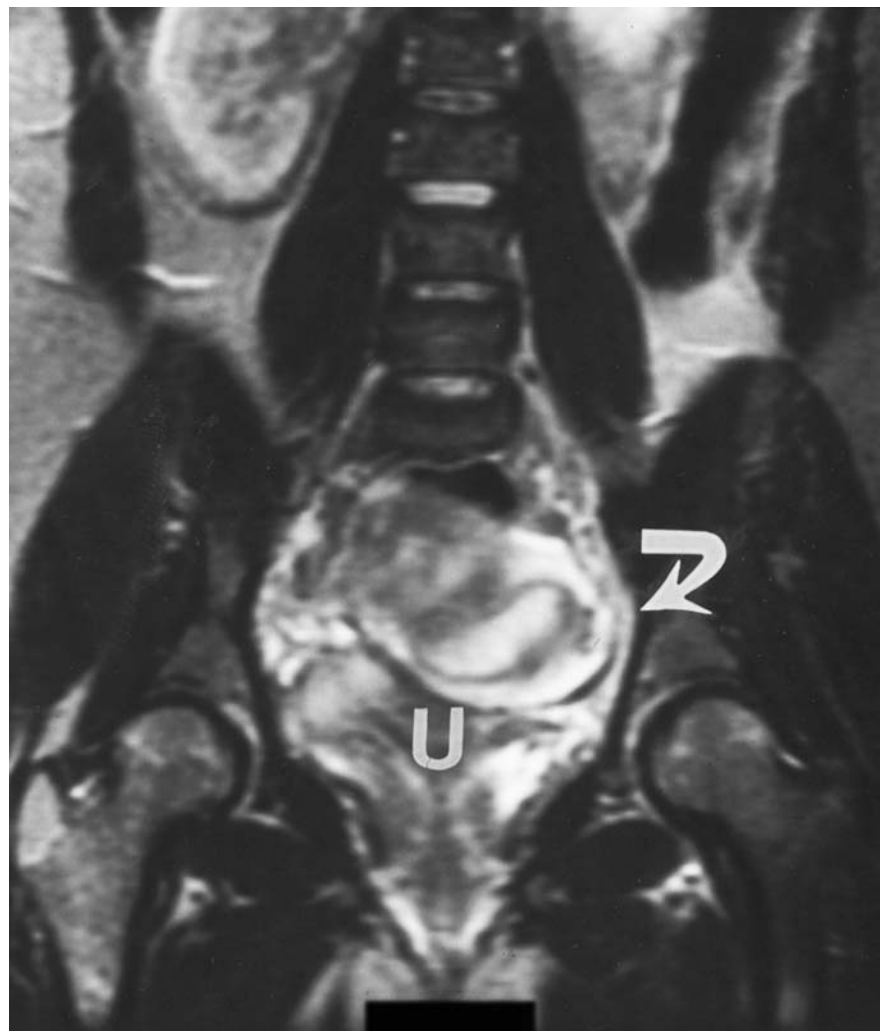
Kaakaji, Y. et al. Am. J. Roentgenol. 2000;174:641-649

## US Dx: PV bleeding ? pregnancy

- IUP with fetal heart beat
- IUP with no fetal heart beat
  - Missed abortion
  - Wrong date
  - Too early
- Pregnancy of unknown location
- Ectopic Pregnancy

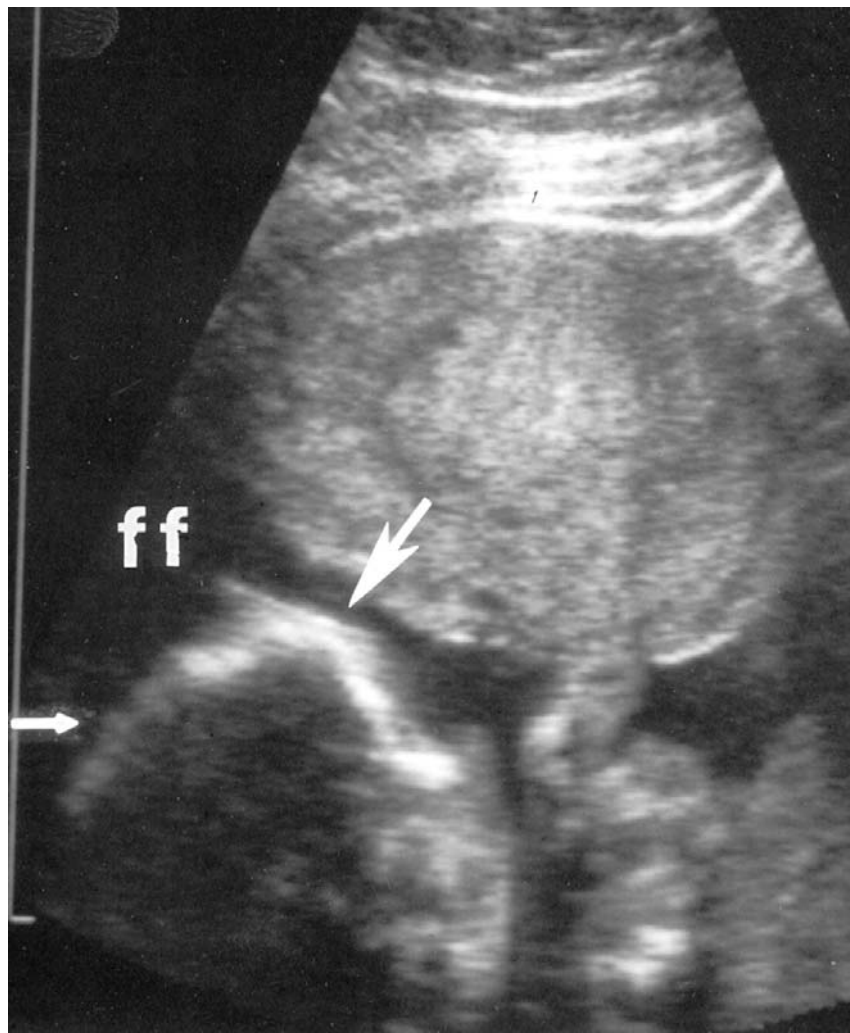


**--32-year-old woman with intra abdominal pregnancy**



**Kaakaji, Y. et al. Am. J. Roentgenol. 2000;174:641-649**

**--32-year-old woman with intra abdominal pregnancy**



**Kaakaji, Y. et al. Am. J. Roentgenol. 2000;174:641-649**




## Pregnancy of Unknown Location (PUL)

- Ectopic pregnancy 11%
  - IUP 33%
  - Failing PUL 54%
  - Persisting PUL 2%
- 
- *?Ambulatory care proved safe*
  - *EP advice @ discharge*



# Pelvic pain



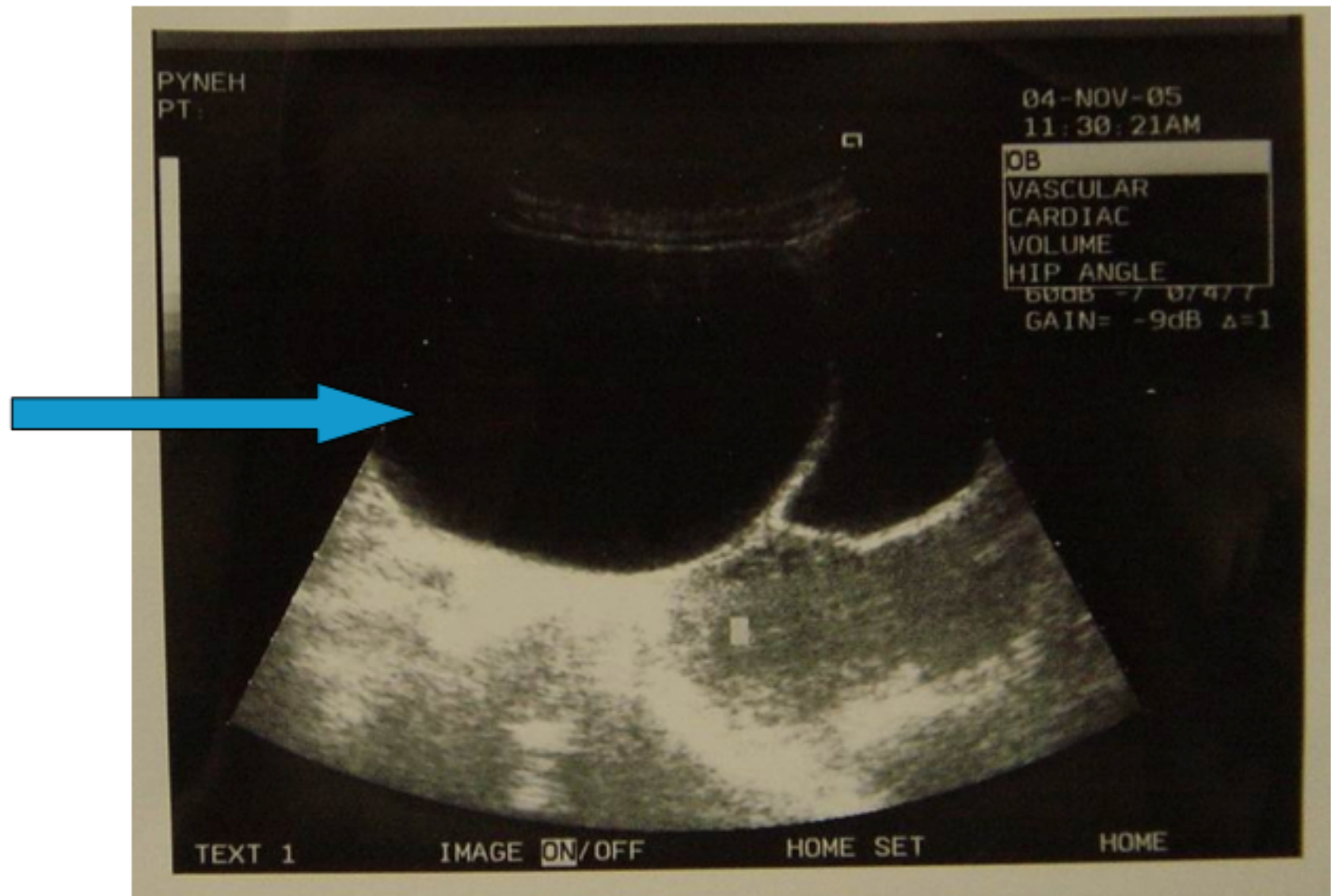
Remember ectopic pregnancy

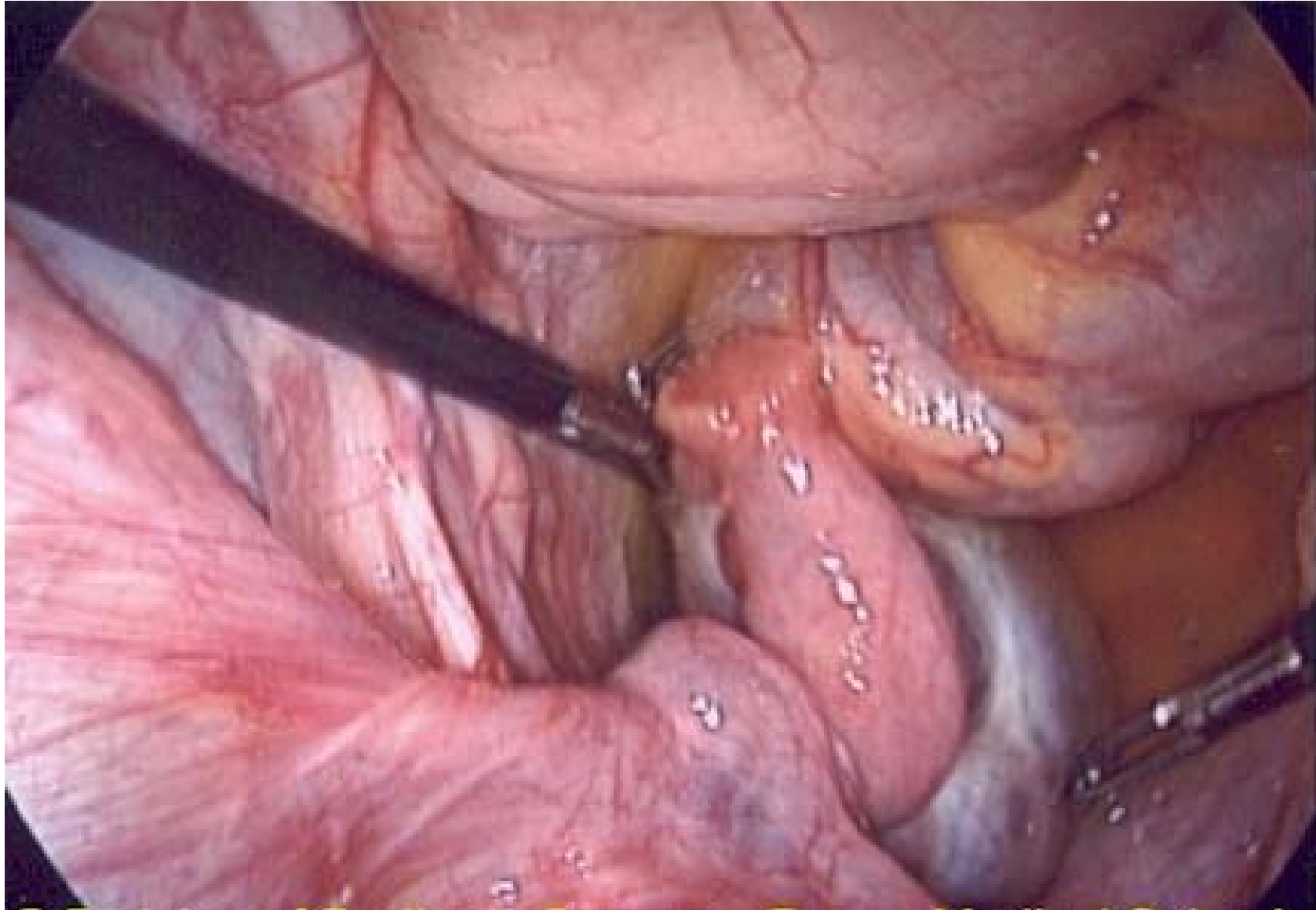
PID (tubo-ovarian abscess etc)

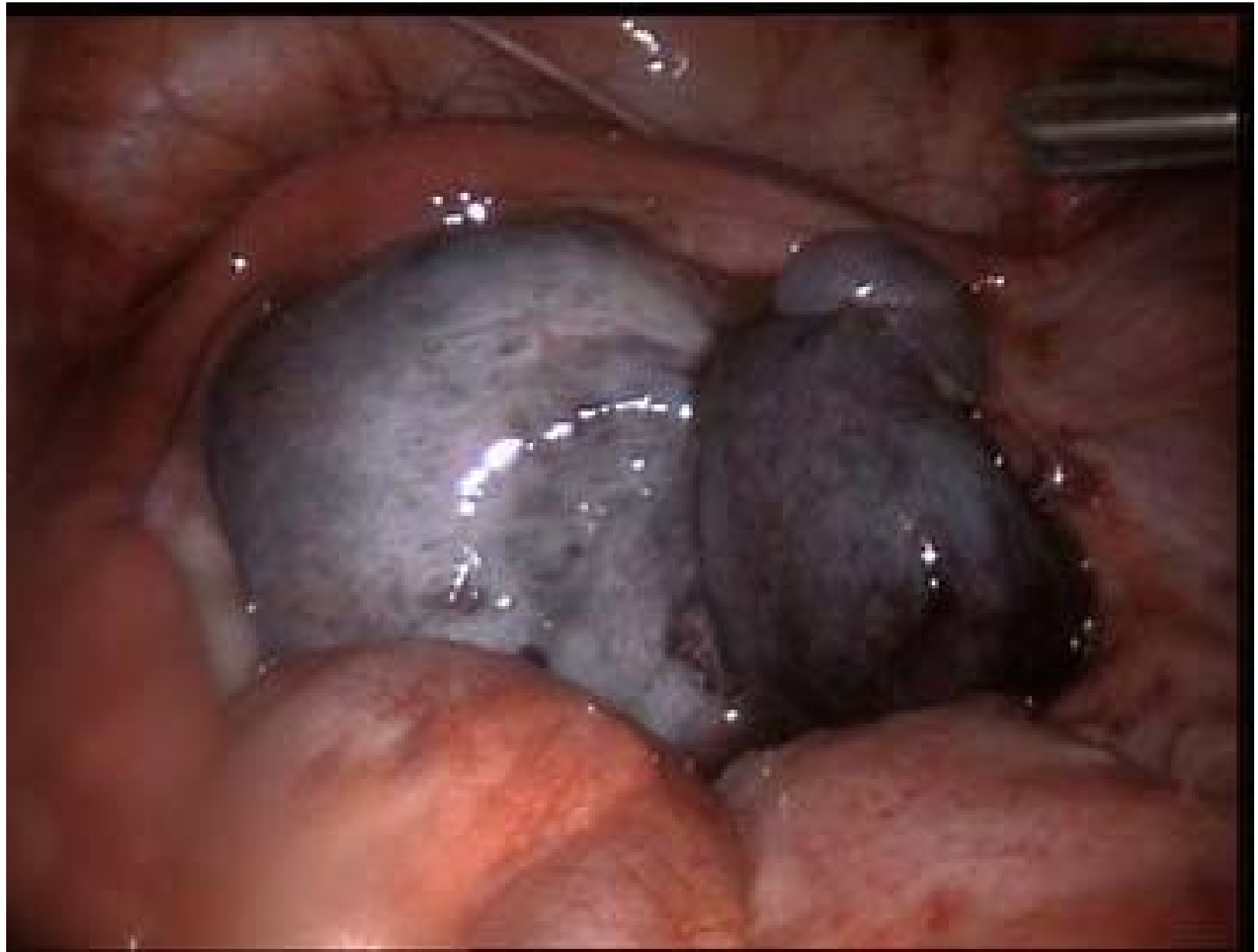Ovary (torsion, rupture, bleeding etc)

Remember non gynecologic causes

# Torsion ovarian cyst







# 3 tenets of OB US

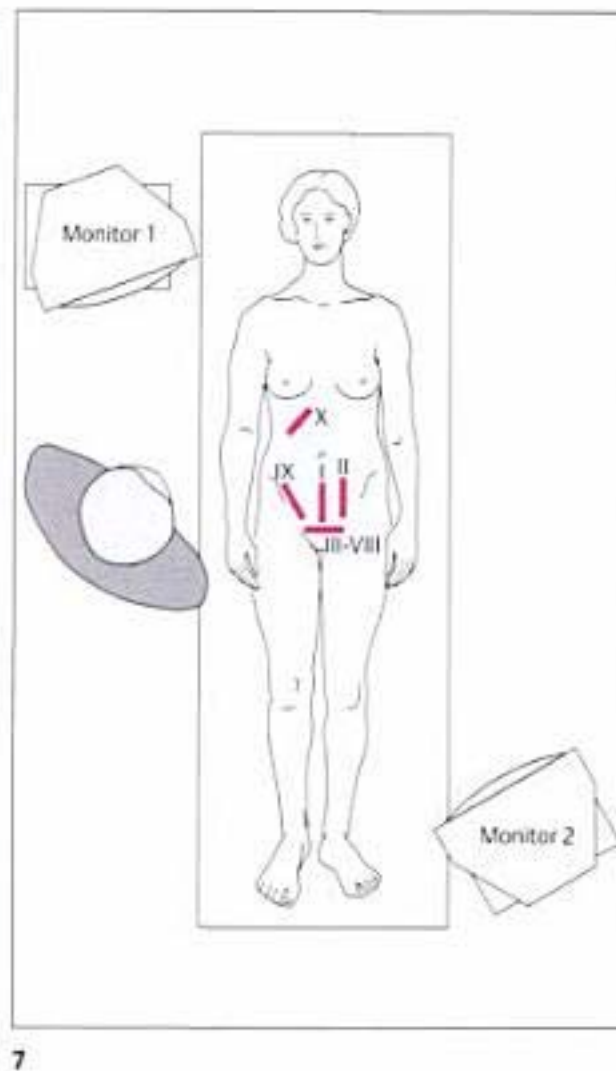
- Location...where is the head
- Location....where is the placenta (or where isn't the placenta)
- Location...where is the heart
- ....how many fetuses

### Abdominal ultrasound

Fig. 1.7 Setup for abdominal ultrasound. The examiner sits to the left of the patient. Separate monitors are provided for the examiner and patient. I = Midsagittal scan, II = lateral sagittal scan, III-VIII = suprasymphyseal transverse scans, IX and X = oblique scans.

Fig. 1.8 Transducer placement for a midsagittal scan.

Fig. 1.9 Transducer placement for a suprasymphyseal transverse scan.



7



8

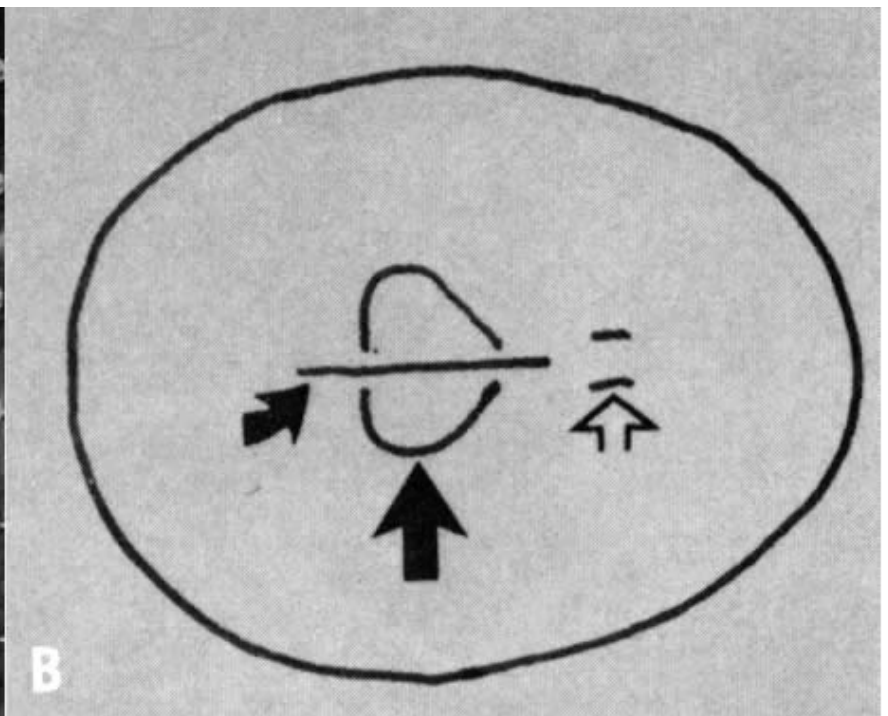
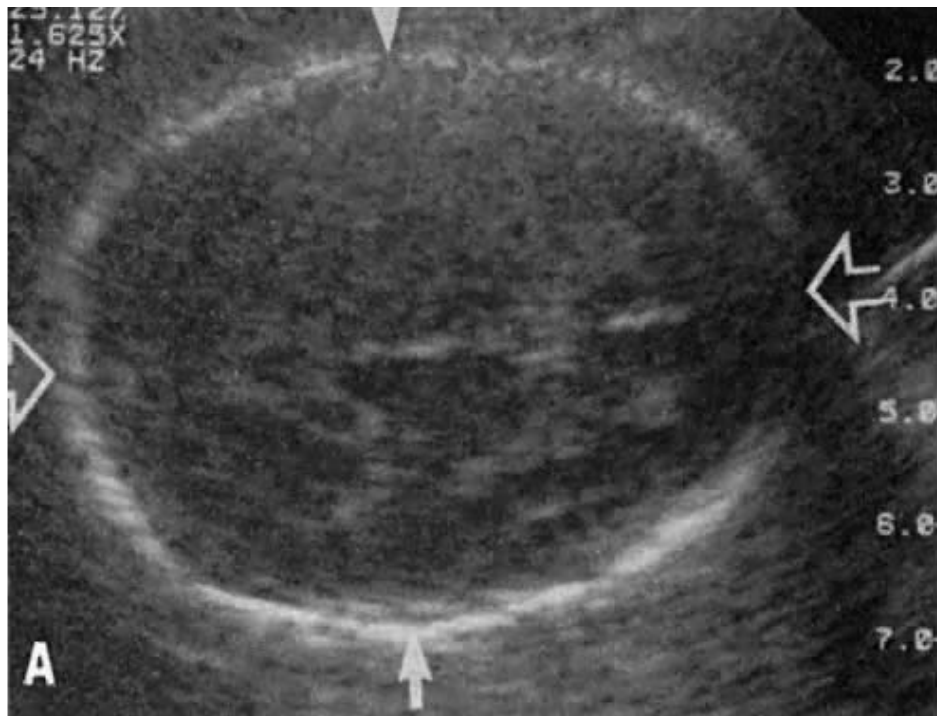


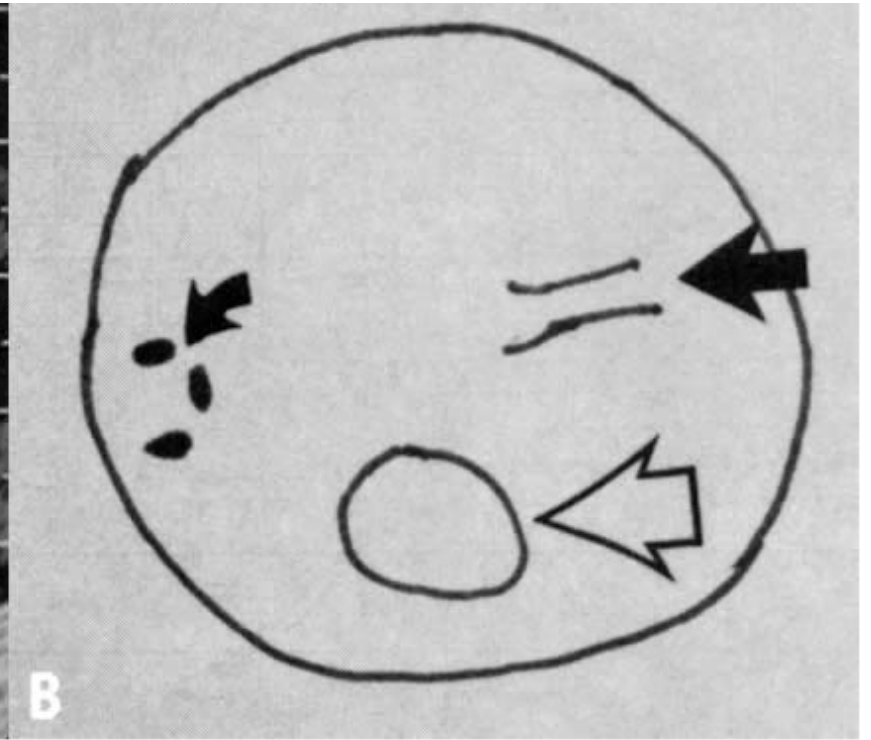
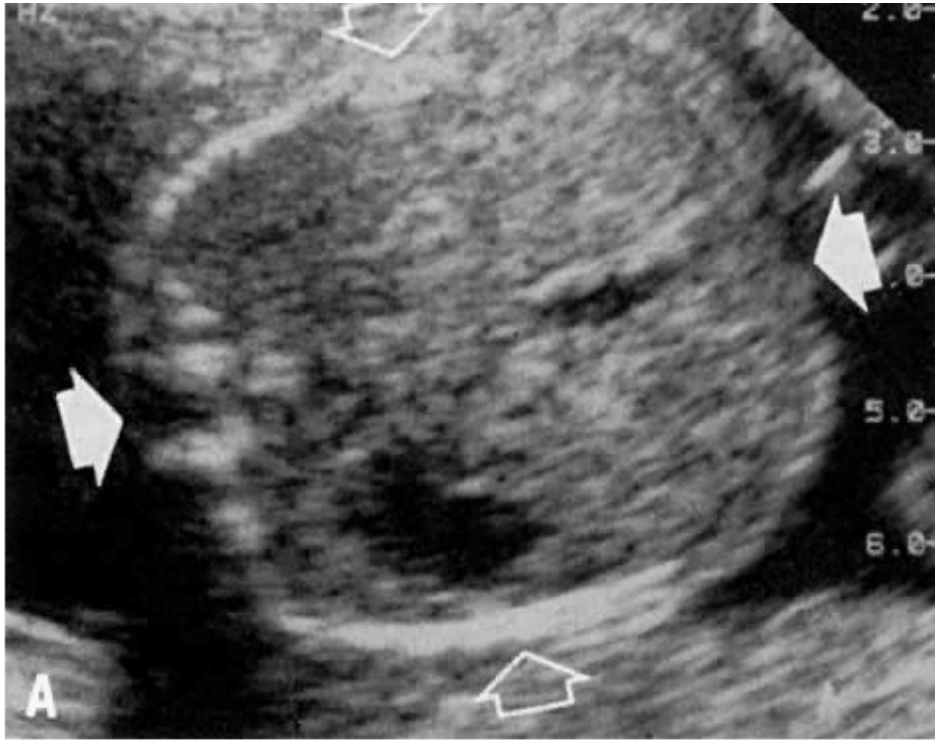
9

$$\text{Weight} = 0.1 \times \text{AC}^3$$

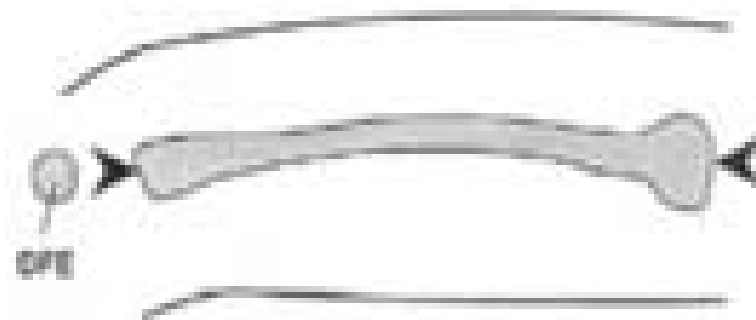
- Works for fetuses 1200-3800g
- AC 22.9-33.6 cm
- About 70% accurate for birth weight prediction
- Underestimates low birth weight <1200 and overestimates >3800g








## FETAL FEMUR LENGTH



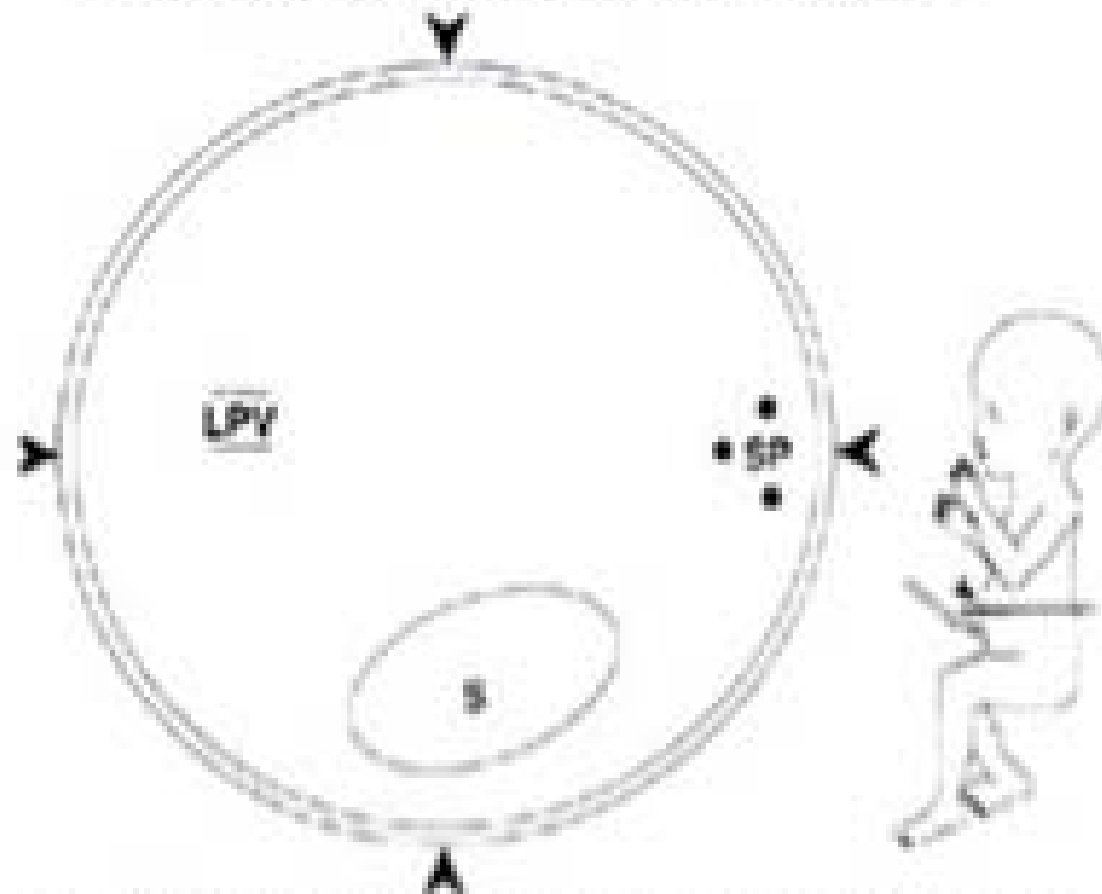
DFE: distal femoral epiphysis



Source: Callen, Peter, "Ultrasonography in Obstetrics and Gynecology", 3<sup>rd</sup> edition, 1994, WB Saunders Company, Philadelphia.

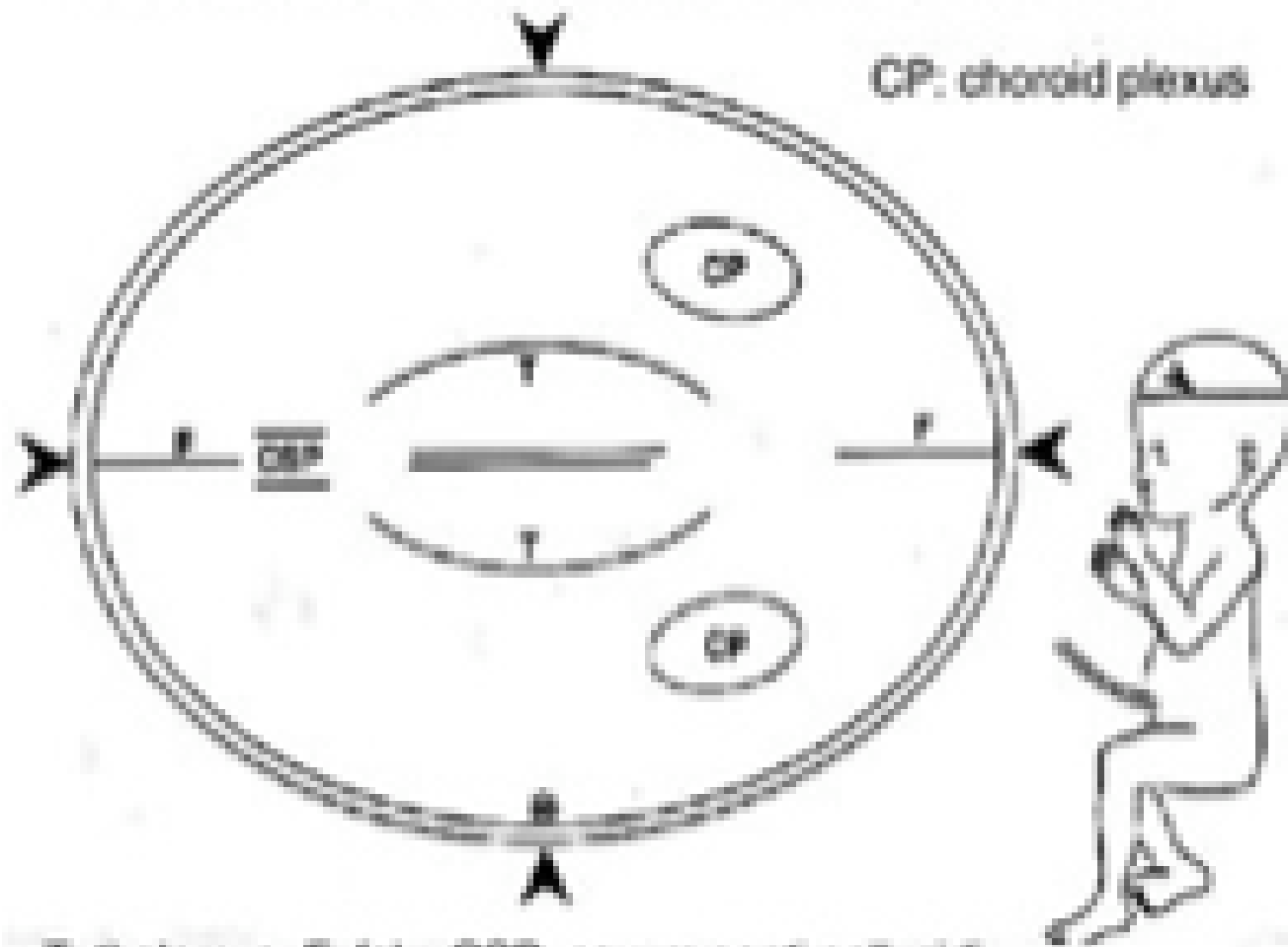


## FETAL ABDOMINAL CIRCUMFERENCE

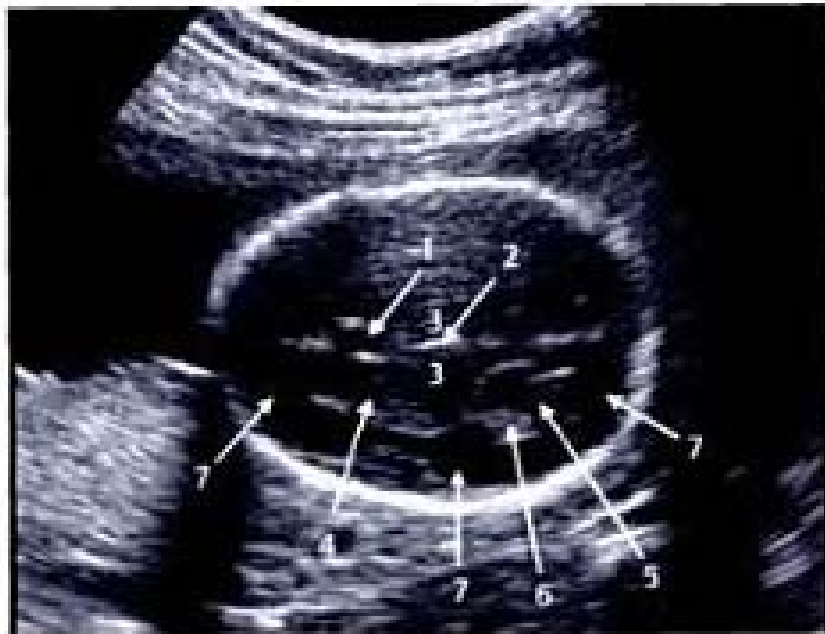


LPV: left portal vein   SP: spine   S: fetal stomach

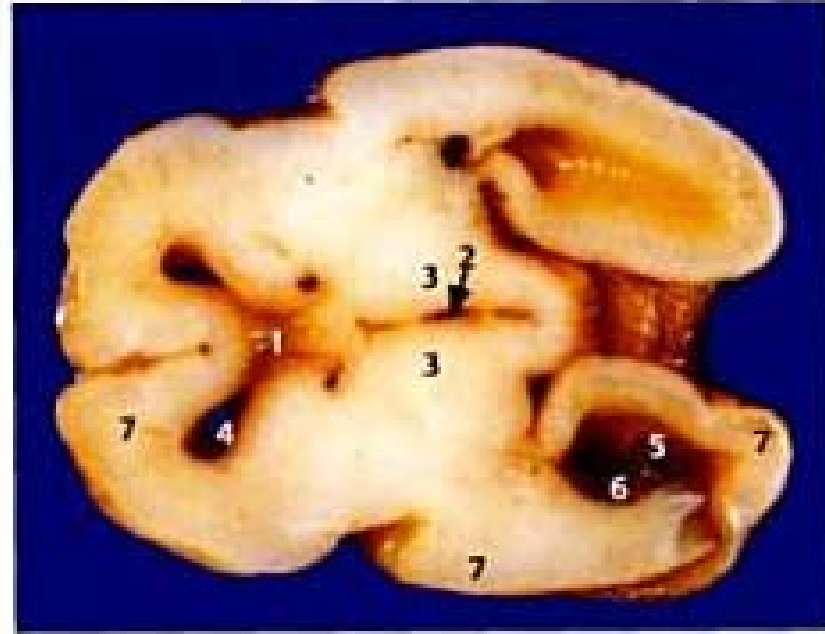
## FETAL HEAD MEASUREMENTS (BPD, HC)



T: thalamus F: falx CSP: cavum septi pellucidum



11



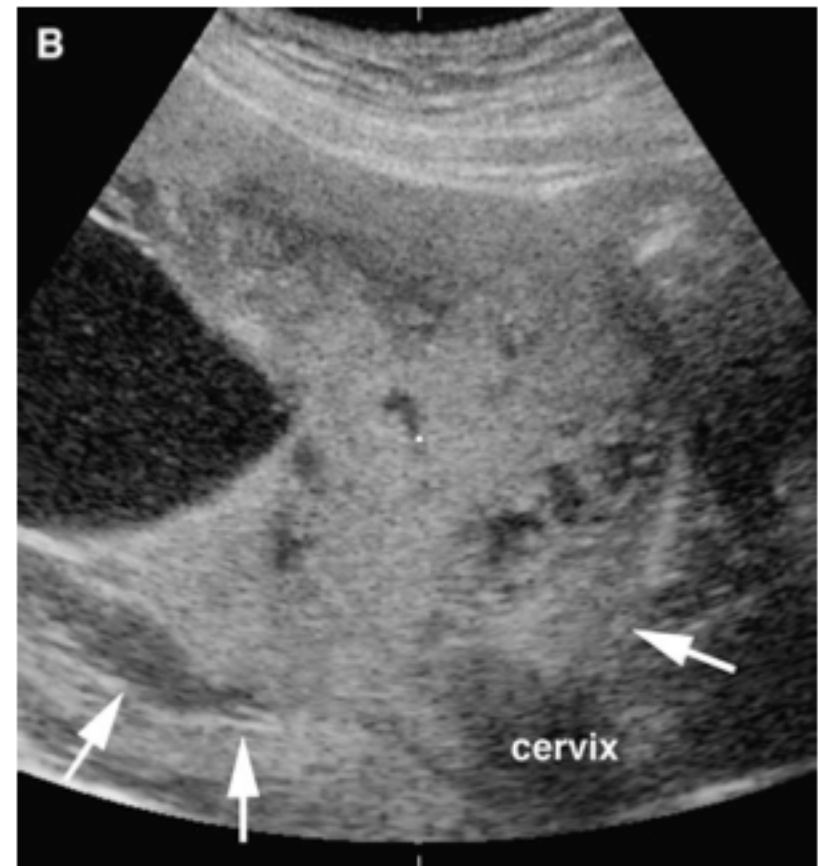
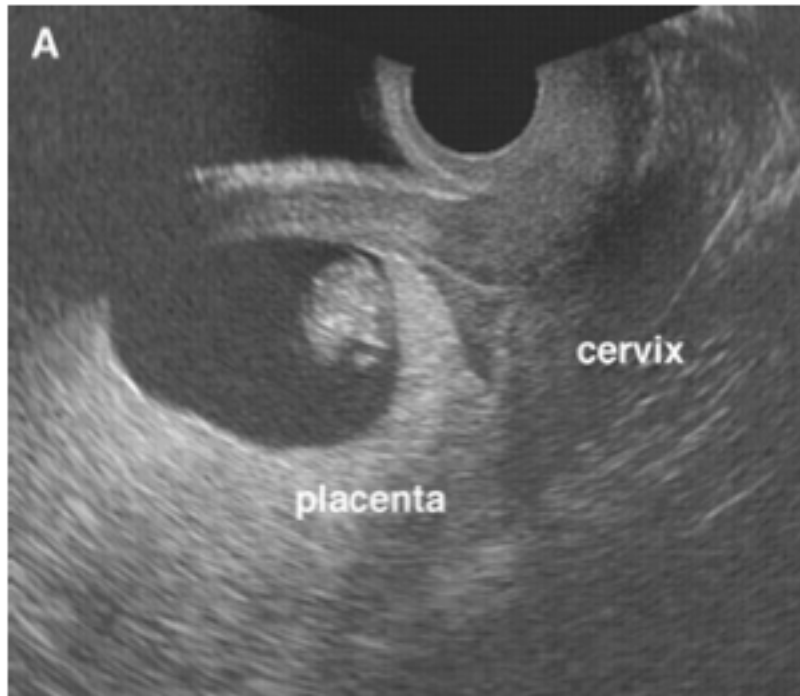
12

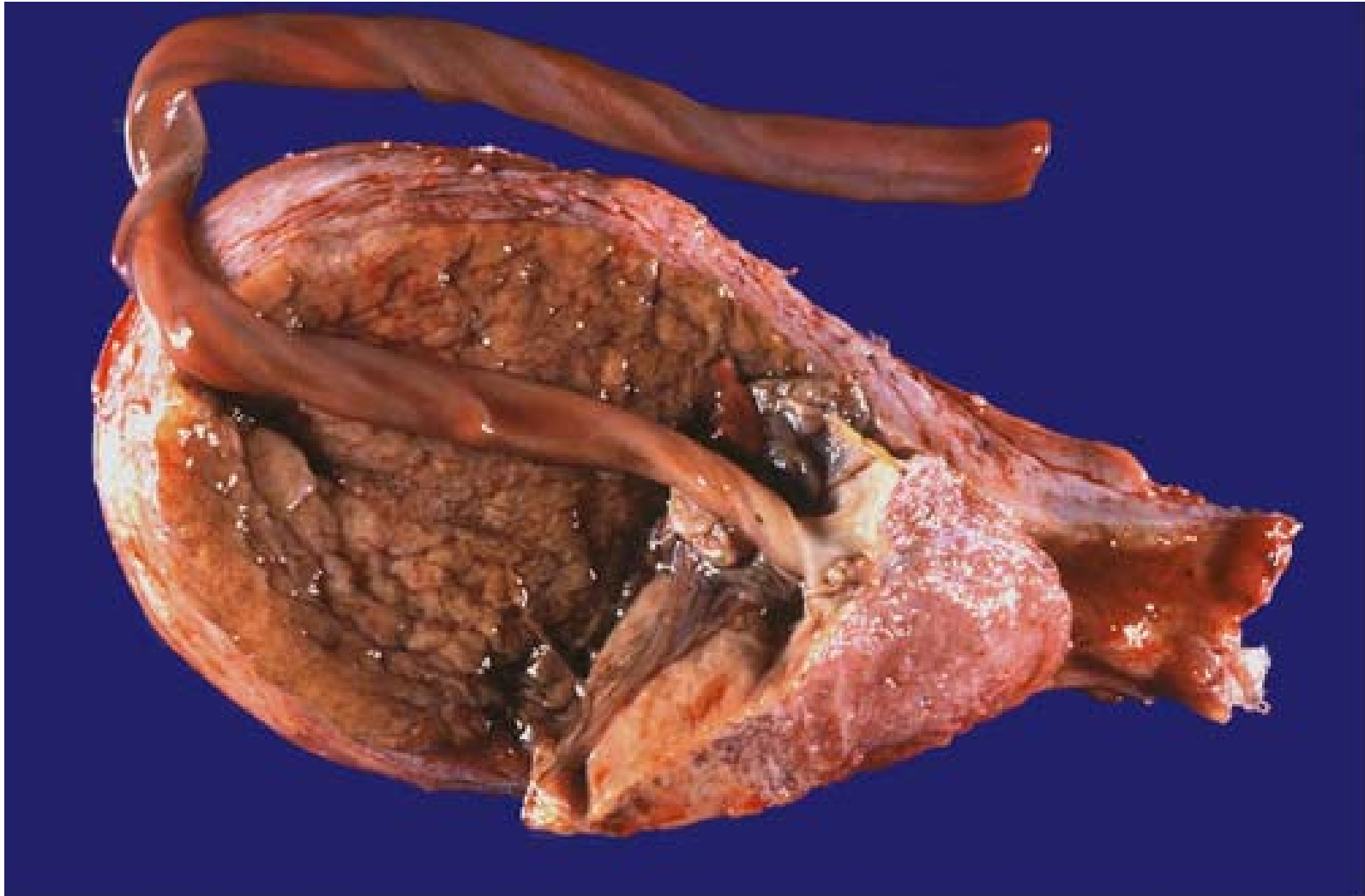Fig  
cip  
mi  
ho  
ho  
pli

Fig  
sp

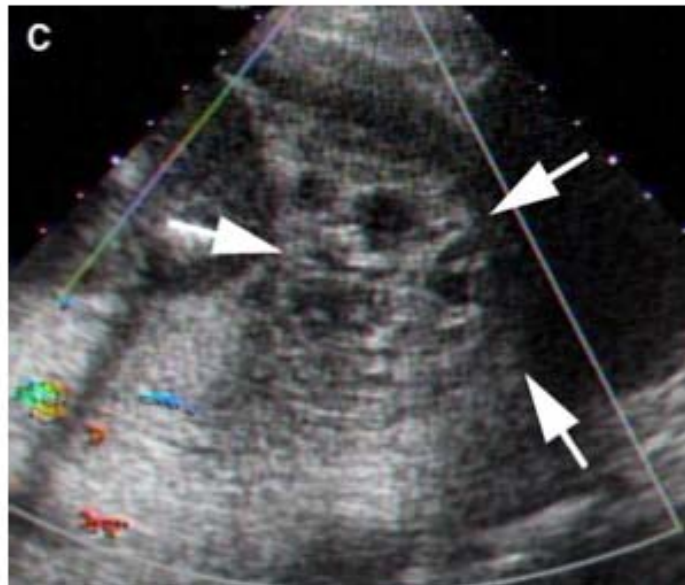
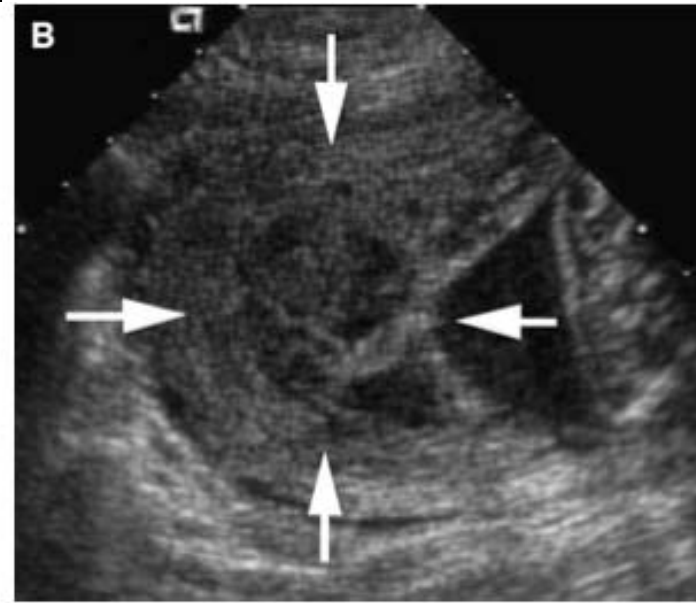
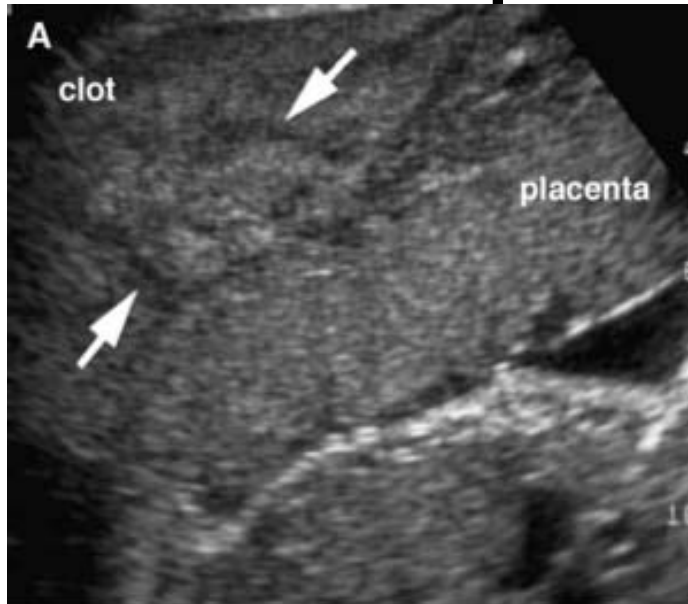


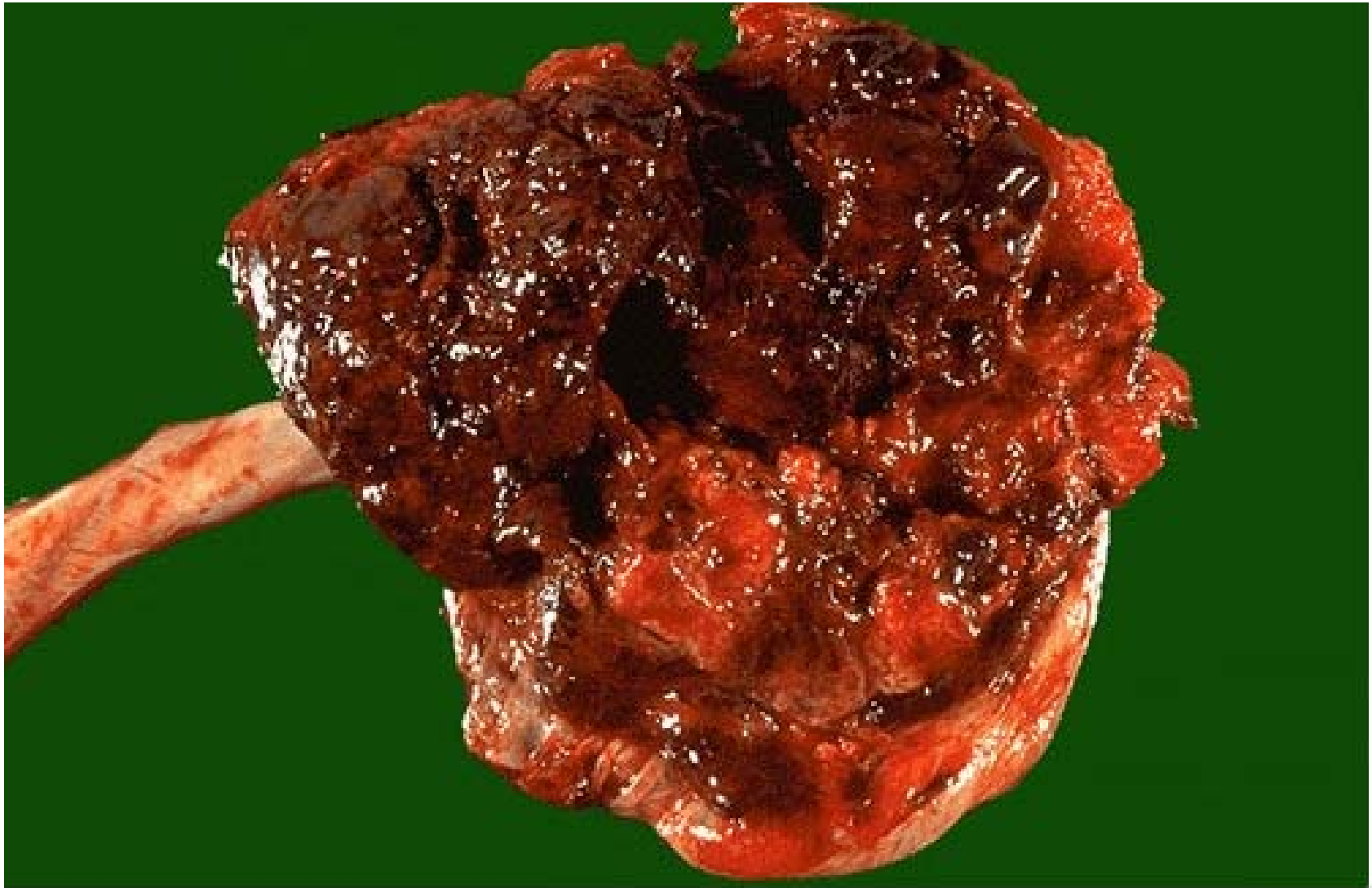# Placenta previa





# Abruptio placenta





“Miles on the ultrasound odometer will not only sharpen sonographic skills but also will help the EP to better communicate with nonpregnant patients presenting with abdominal pain.

There is a fairly specific barometer already in place to gauge one gynecologic ultrasound skills: a seasoned EP sonographer never skips over the chart of a young woman with right lower quadrant pain.” - M.lambert